Portuguese Journal of
Dermatology and Venereology

ISSN: 2795-501X
e-ISSN: 2795-5001

Formerly The Journal of the Portuguese Society of Dermatology and Venereology (SPDV)

Vol. 81 • N.º 4 • October-December 2023 www.portuguesejournalofdermatology.com Indexed in SciELO, EBSCO, Google Scholar, DOAJ, SHERPA/RoMEO, ÍndexRMP, Scopus and Embase

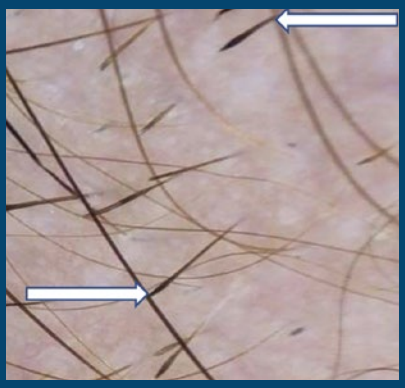

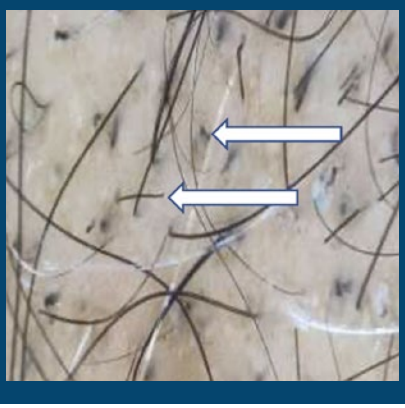

In this issue:

Portuguese Journal of Dermatology and Venereology

Permanyer
www.permanyer.com


Feliz Natal e
Próspero Ano Novo,
Deseja a Direção da SPDV

cantabria labs
celebrate life

HIPERIDROSE?
Há solução!

Glicopirrónio Axidrox
8 mg/g Creme
Glicopirrónio

Primeiro medicamento tópico indicado para a **hiperidrose**[1]

NOVO

Nome do medicamento: **Glicopirrónio Axidrox 8 mg/g Creme**
Apresentação: **Frasco 50 g**
Reg. no INFARMED nº: **5858741**
PVP: **46,41€**
Classificação: **MSRM**
Regime de Comp.: **NA**

AXIDROX/AN/12/23

DISPONÍVEL EM JANEIRO DE 2024

Para mais informações
consulte o IERCM

VM/AXIDROX/AN/12/23

***Glicopirrónio Axhidrox está indicado para o tratamento tópico da hiperidrose axilar primária grave em adultos.**[1]

1. Resumo das características do medicamento Glicopirrónio Axidrox 8mg/g Creme. Disponível em https://extranet.infarmed.pt/INFOMED-fo/ e https://www.cantabrialabs.pt/wp-content/uploads/2023/10/AXIDROX_IECRCM.docx.pdf

LA ROCHE-POSAY
LABORATOIRE DERMATOLOGIQUE

INOVAÇÃO

EFFACLAR DUO+M

ACNE JOVEM

MODULAÇÃO DO MICROBIOMA

REDUZ OS **FILOTIPOS 1A1** DA **C. ACNES** E ATUA SOBRE O MICROBIOMA

REDUZ A **SEVERIDADE DA ACNE** E
HIPERPIGMENTAÇÃO PÓS-INFLAMATÓRIA
ANTI-RECIDIVA
INDICADO EM **TERAPÊUTICA ADJUVANTE**

Testado em imperfeições severas.
Testado em todos os fototipos.
Testado a partir dos 10 anos.

AQUA POSAE FILIFORMIS + PROCERAD + ÁCIDO SALICÍLICO + LHA + ZINCO + NIACINAMIDA + MANOSE

POTENCIA O TRATAMENTO EM TERAPÊUTICA ADJUVANTE

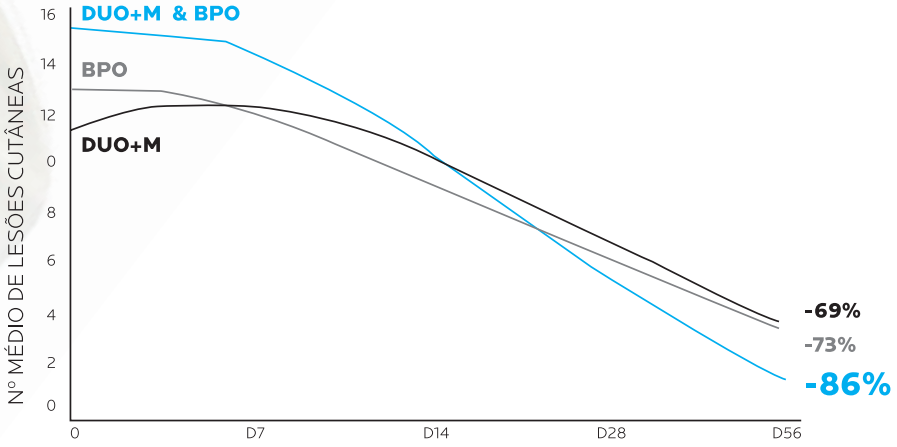

Estudo clínico, com 64 doentes em 3 grupos: EFFACLAR DUO+, BPO e EFFACLAR DUO+ em combinação com BPO, durante 56 dias.

[PHYLOBIOMA] NOVO
INGREDIENTE ATIVO VEGETAL
RICO EM POLIFENÓIS
ATUA ESPECIFICAMENTE NO **FILOTIPO IA1**
da Cutibacterium Acnes
& REEQUILIBRAR O MICROBIOMA

TESTADO EM COMBINAÇÃO COM
AS PRINCIPAIS TERAPÊUTICAS ANTI-ACNE
BPO, ADAPALENO, EPIDUO®, ÁC. AZELAICO, RETINÓIDES, ERITROMICINA E/OU TRETINOÍNA, ANTIBIÓTICOS TÓPICOS.

LA ROCHE-POSAY. A EXIGÊNCIA DERMATOLÓGICA.

LA ROCHE POSAY
LABORATOIRE DERMATOLOGIQUE

NOVO

LIPIKAR
LAIT UREA 10%

LOÇÃO HIDRATANTE DE TRIPLA AÇÃO, COM UREIA
ANTI-DESCAMAÇÃO, ANTI-RUGOSIDADE, APAZIGUANTE

[10% UREIA + MANTEIGA DE KARITÉ + HEPES + ALANTOÍNA]

INDICADO PARA **XEROSE CUTÂNEA,**
XEROSE SENIL, ICTIOSE, QUERATOSE PILAR, PSORÍASE

TEXTURA DE RÁPIDA ABSORÇÃO

EFICÁCIA COMPROVADA EM SÉNIORES, ADULTOS E CRIANÇAS

TESTADO EM PELE SENSÍVEL

XEROSE CUTÂNEA (DERMASCORE®)

-98.6%[1]

DIMINUIÇÃO SIGNIFICATIVA DA XEROSE CUTÂNEA LOGO APÓS UMA ÚNICA APLICAÇÃO

1. Estudo clínico: 42 pacientes, com xerose cutânea nas pernas (Dermascore® grau≥ 4). Avaliação Clínica da xerose cutânea de acordo com Dermascore® a D0 /T0 após uma aplicação.

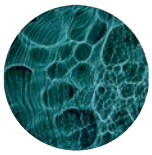

UREIA 10%

UMA MOLÉCULA ESSENCIAL PARA UMA HIDRATAÇÃO ADEQUADA E PARA PRESERVAR A INTEGRIDADE DA BARREIRA CUTÂNEA

AÇÃO HIDRATANTE
MELHORA A FUNÇÃO BARREIRA
AÇÃO QUERATOLÍTICA



HEPES

EFEITO QUERATOLÍTICO NATURAL
REFORÇA A HIDRATAÇÃO

MANTEIGA DE KARITÉ

FORTALECE A BARREIRA CUTÂNEA
NUTRE A PELE

LA ROCHE-POSAY. A EXIGÊNCIA DERMATOLÓGICA.

VICHY
LABORATOIRES

LIFTACTIV SPECIALIST
SÉRUM B3
MANCHAS

5% NIACINAMIDA
1% ÁCIDO TRANEXÂMICO
8% COMPLEXO PEELING
[ÁCIDO GLICÓLICO + HEPES + UREIA]
VITAMINA CG

AÇÃO SINÉRGICA NAS HIPERPIGMENTAÇÕES
CLINICAMENTE COMPROVADO

- ✓ **REDUZ AS MANCHAS ESCURAS**
- ✓ **MELHORA A TEZ DA PELE**
- ✓ **MELHORA A APARÊNCIA DA PELE**

EFICÁCIA NAS MANCHAS ESCURAS PERSISTENTES*

-38%
MASI SCORE

ANTES

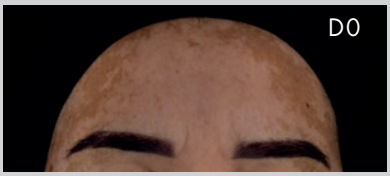

DEPOIS

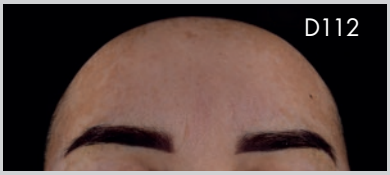

*MASI SCORE. 34 indivíduos (fototipo II a VI). Utilização Liftactiv Sérum B3 + Capital Soleil UV-AGE SPF50+, 5 meses.

EAU THERMALE
Avène
LABORATOIRE DERMATOLOGIQUE

CLEANANCE
COMEDOMED
CONCENTRADO ANTI-IMPERFEIÇÕES

eficácia comprovada a partir de 7 dias*

Atua nos microcomedões a origem das imperfeições
Silybum Marianum Fruit Extract

Testado em mais de 4,600 doentes

1 ano sem recidivas**

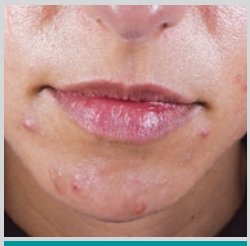
ANTES

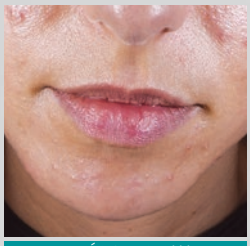
APÓS 2 MESES***

PARA A PELE OLEOSA DE TENDÊNCIA ACNEICA

Eau Thermale Avène,
a confiança de uma pele saudável

*Estudo de tolerância e eficácia sob controlo dermatológico em 51 indivíduos, utilização de Cleanance Comedomed duas vezes por dia durante 56 dias.
**Estudo clínico observacional internacional, 85% dos indivíduos sem recidiva da acne após 1 ano (de acordo com a definição de recidiva do protocolo GEA > 3 que requer a introdução de um tratamento medicamentoso - oral ou tópico), 54 indivíduos, 2 aplicações por dia de Cleanance Comedomed durante 1 ano.
***Estudo clínico durante 2 meses em 36 indivíduos 2 aplicações por dia.

SOCIO-ENVIRONNEMENTAL IMPACT GREEN IMPACT INDEX A B C D by Pierre Fabre

Método desenvolvido por PIERRE FABRE Group.
Mais informações em: www.eau-thermale-avene.com

AV-365-11-23

Portuguese Journal of
Dermatology and Venereology

ISSN: 2795-501X
e-ISSN: 2795-5001

Formerly The Journal of the Portuguese Society of Dermatology and Venereology (SPDV)

Vol. 81 • N.º 4 • October-December 2023 www.portuguesejournalofdermatology.com *Indexed in SciELO, EBSCO, Google Scholar, DOAJ, SHERPA/RoMEO, and ÍndexRMP*

Administration and Secretariat:
Sociedade Portuguesa de Dermatologia,
Rua dos Argonautas, N° 3A, Sala 2
1990-014 Lisboa
Tel. +351.21 139 00 54
Tel. +351.91 515 85 00/50
e-mail: geral@spdv.com.pt

Register:
Isenta de Registo ERC ao abrigo do decreto regulamentar 8/99 de 9/6 art. 12 n°1A

Edition:
500 editions
Free distribuition to members

Original papers should be deposited in their electronic version through the following URL:

https://publisher.portuguesejournalofdermatology.permanyer.com

Permanyer
www.permanyer.com

Permanyer
Mallorca, 310 – Barcelona (Cataluña), España
permanyer@permanyer.com

www.permanyer.com

ISSN: 2795-5001
Ref.: 7596AP224

Portuguese Journal of Dermatology and Venereology

Permanyer

Check for updates

Port J Dermatol and Venereol.

EDITORIAL

2023-2024 – Where we are and where we want to be!

2023-2024 – Onde estamos e para onde queremos ir!

*Tiago Torres[1,2,3a] and Margarida Gonçalo[4,5b]**

[1]Instituto de Ciências Biomédicas Abel Salazar, University of Porto, Porto; [2]Department of Dermatology, Centro Hospitalar Universitário do Porto, Porto; [3]Dermatology Clinic, Instituto Médico de Estudos Imunológicos, Porto; [4]Centro Hospitalar e Universitário de Coimbra, Coimbra; [5]Faculdade de Medicina, Universidade de Coimbra, Coimbra. Portugal

ORCID: [a]0000-0003-0404-0870; [b]0000-0001-6842-1360

For the Portuguese Journal of Dermatology and Venereology, 2023 was a year characterized by its growth, the quality of the published manuscripts, and the continuous collaboration of the journal's reviewers.

One of the most notable achievements of the Portuguese Journal of Dermatology and Venereology in 2023 was its substantial growth. In a world where knowledge evolves at an unprecedented rate, we have had a significant increase in submissions from all over the world. This growth is the evidence of journal's commitment to disseminating dermatology knowledge within the scientific community.

This year, we were privileged to publish several high-quality manuscripts. The rigorous peer review process, combined with the experience and dedication of our esteemed reviewers, ensures that each publication is of the highest standard. We take this opportunity to extend our sincere gratitude to all our authors for trusting us with their research and to our reviewers for their invaluable contributions. Your commitment to excellence has been fundamental in raising the quality of the journal.

Looking ahead, we are excited to announce that the Portuguese Journal of Dermatology and Venereology has applied for indexing in PubMed Central. This milestone is proof of our relentless pursuit of broader visibility and reach for the journal. Once indexed, we will be able to reach an even wider audience.

As we turn the page to a new year, we remain dedicated to our mission, committed to maintaining our high standards of scientific quality.

In closing, we extend our warmest thanks to everyone who contributed to the success of the Portuguese Journal of Dermatology and Venereology in 2023. We look forward to the exciting opportunities and challenges that the new year will bring. Together, we will continue to push the boundaries of dermatological research and medical education.

***Correspondence:**
Margarida Gonçalo
E-mail: mmgoncalo@gmail.com

Received: 16-10-2023
Accepted: 23-10-2023
DOI: 10.24875/PJDV.M23000047

Available online: 20-12-2023
Port J Dermatol and Venereol. 2023;81(4):231
www.portuguesejournalofdermatology.com

Portuguese Journal of Dermatology and Venereology

Permanyer

Check for updates

Port J Dermatol and Venereol.

ORIGINAL ARTICLE

Trichoscopy in alopecia areata and trichotillomania

Tricoscopia na alopecia areata e tricotilomania

*Saurabh Sharma[1a], Komalpreet Kaur[1b], Jasleen Kaur[1c], and Roopam Bassi[2d]**

[1]Department of Dermatology, Venereology and Leprosy; [2]Department of Physiology. Sri Guru Ram Das Institute of Medical Sciences and Research, Amritsar, Punjab, India

ORCID: [a]0000-0003-2808-136X; [b]0009-0002-6816-2391; [c]0000-0002-7428-1445; [d]0000-0001-8600-0818

Abstract

Background: Alopecia areata (AA) and trichotillomania (TTM) belong to non-cicatricial alopecia. These disorders may have similar clinical features with different therapeutic protocols and prognoses. Trichoscopy has proved to be an office-based tool that helps in the diagnosis and differentiation of different types of alopecia. **Objective:** Our objective is to differentiate and diagnose AA and TTM based on trichoscopic features. **Methods:** The present cross-sectional and observational study was conducted on 86 patients presenting with complaints of hair loss in the outpatient department from January 2019 to September 2020. A scalp examination was done, followed by the dermatoscopic examination with a Dermlite DL4 dermatoscope. **Results:** The percentage of black dots was higher in AA as compared to TTM. Broken hair at equal lengths was observed in AA, whereas broken hair at varying lengths was seen in TTM. Coiled hair, V-sign, and flame hair were only seen in TTM. **Conclusion:** The combination of black dots, broken hair, and exclamation mark favored the diagnosis of AA. Hair breaking at varying lengths, the V sign, flame hair, and coiled hair were exclusively seen in TTM.

Keywords: Trichoscopy. Alopecia areata. Trichotillomania. Non-cicatricial alopecia.

Resumo

Introdução: Alopecia areata (AA) e trichotillomania (TTM) pertencem ao grupo das alopécias não cicatriciais. Esses distúrbios podem ter características clínicas semelhantes mas têm diferentes protocolos terapêuticos e prognóstico. A tricoscopia provou ser uma ferramenta de acesso fácil que ajuda no diagnóstico e diferenciação de AA e TTM. **Objetivo:** Nosso objetivo é diferenciar e diagnosticar AA e TTM com base em recursos tricoscópicos. **Métodos:** O presente estudo transversal e observacional foi realizado em 86 pacientes que apresentaram queixas de perda de cabelo no departamento ambulatorial de janeiro de 2019 a setembro de 2020. O exame objetivo do couro cabeludo foi seguido pelo exame dermatoscópico com um dermatoscópio Dermlite DL4. **Resultados:** A percentagem de pontos pretos foi maior na AA em comparação com o TTM. Cabelos quebrados em comprimentos iguais foram observados na AA, enquanto cabelos quebrados em comprimentos variados foram vistos em TTM. Cabelos enrolados, sinais em V e cabelos em chamas eram vistos apenas no TTM. **Conclusão:** A combinação de pontos pretos, cabelos quebrados e ponto de exclamação favoreceu o diagnóstico de AA. Cabelos quebrados em comprimentos variados, o sinal V, cabelos em chamas, e cabelos enrolados foram vistos exclusivamente no TTM. A diferença na percentagem de características dermatoscópicas especificas de cada doença é estatisticamente significativa.

Palavras-chave: Tricoscopia. Alopecia areata. Tricotilomania. Alopecia não cicatricial.

***Correspondence:**
Roopam Bassi
E-mail: drroopamsharma@yahoo.co.in

Received: 23-06-2023
Accepted: 02-10-2023
DOI: 10.24875/PJDV.23000053

Available online: 20-12-2023
Port J Dermatol and Venereol. 2023;81(4):232-238
www.portuguesejournalofdermatology.com

Introduction

Alopecia areata (AA) and trichotillomania (TTM) are two common forms of non-scarring hair loss encountered in clinical practice. TTM is a compulsive disorder characterized by the irresistible urge to pull out hair leading to bizarre-shaped patches of hair loss[1]. AA is an autoimmune disorder that typically presents with sharply demarcated patches of hair loss. Since the treatment strategies and prognosis of these disorders are different, it is important to differentiate them using non-invasive methods such as dermatoscopy since scalp biopsy is not frequently accepted by the patients. Concerning the dermatoscopic features, not much work has been done on TTM compared to AA.

Methods

The present cross-sectional and observational study was conducted in the outpatient department of Dermatology, Venereology, and Leprosy in Sri Guru Ramdas Institute of Medical Sciences and Research, Sri Amritsar, between January 2019 and September 2020.

Only patients with the clinical diagnosis of AA or TTM were included. Any other scalp disease, such as androgenetic alopecia, seborrheic dermatitis, and tinea capitis, were excluded from our study. The diseased area of the scalp was examined, and the diagnosis of AA and TTM was made clinically. Well-demarcated patches of hair loss with hair broken at equal lengths favored the diagnosis of AA, whereas irregular patches of hair loss with hair broken at varying lengths favored the TTM diagnosis. TTM patients had a history of relief of stress with picking of hair, unlike AA patients. This macroscopic examination was followed by the dermatoscopic examination of the scalp with Dermlite DL4 dermatoscope to see the various hair follicle structures and hair shaft patterns. Informed consent was taken from each patient. Approval from the Institutional Ethics Committee was taken.

Results were tabulated and analyzed statistically using SPSS Software 19.0 version. Percentages and mean values were calculated wherever applicable. For establishing relation between AA and TTM, correlation coefficient (r) was calculated. Results were considered significant if value of probability ‘p’ < 0.05 and highly significant if ‘p’ < 0.01.

Results

We included 86 patients in the study, 76 patients with AA and 10 patients with TTM. Out of total patients, there were 40 males and 46 females. The mean age of presentation in the study was 30.6 years with a standard deviation of 14.52 years.

Trichoscopic features of AA

Among the 76 patients diagnosed with AA, the most common trichoscopic finding was black dots (Fig. 1) seen in 51 patients (67.1%), broken hair (Fig. 2) seen in 50 patients (65.7%), short vellus hair (Fig. 3) seen in 36 patients (47.3%), tapering hair (Fig. 4) in 27 patients (35.5%), yellow dots (Fig. 5) in 23 patients (30.2%), pigtail hair in 18 patients (23.6%), coudability hair (Fig. 6) in 16 patients (21.05%), tulip hair (Fig. 7) in 8 patients (10.5%), upright regrowing hair in 6 (7.89%) patients, and split ends (Fig. 8) in 4 (5.26%) patients (Table 1).

Trichoscopic features of TTM

Out of 10 patients in the TTM group, the most common trichoscopic features were broken hair at varying lengths (Fig. 9) seen in 10 patients (100%), black dots in 9 (90%) patients, upright regrowing hair, split ends, and coiled hair (Fig. 10) were seen in 7 (70%) patients each, V sign (Fig. 11) and flame hair (Fig. 12) in 4 (40%) patients each, tulip hair in 3 (30%) patients, and tapering hair in 1 (10%) patient (Table 2).

Comparing trichoscopic features in AA and TTM

Black dots were seen in 51 (67.1%) patients of AA and 9 (90%) patients of TTM. Broken hair was seen in 50 (65.7%) patients of AA and 10 (100%) patients of TTM. Tapering hair was seen in 27 (35.5%) patients of AA and 1 (10%) patient of TTM. Tulip hair was seen in 8 (10.5%) patients of AA and 3 (30%) patients of TTM. Split ends were seen in 4 (5.26%) patients of AA and 7 (70%) patients of TTM. Upright regrowing hair was seen in 6 (7.89%) patients of AA and 7 (70%) patients of TTM.

The difference between AA and TTM in the percentage of black dots, broken hair, tapering hair, tulip hair, split ends, and upright-growing hair was statistically significant (Table 3).

Discussion

AA is one of the most common forms of hair loss seen by dermatologists and accounts for 25% of all cases of alopecia[2]. In the general population, the prevalence was estimated at 0.1-0.2%, with a lifetime risk

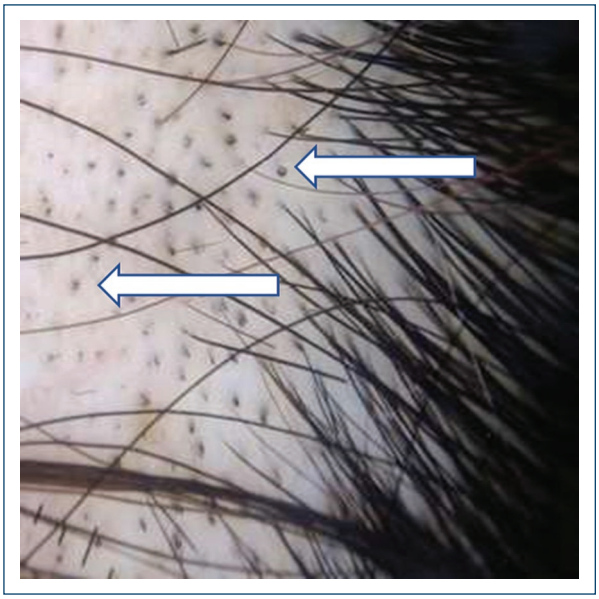

Figure 1. Black dots.

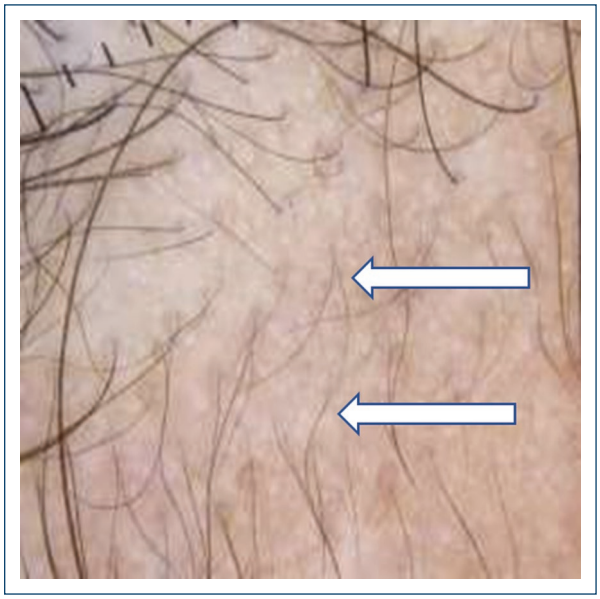

Figure 3. Short vellus hair.

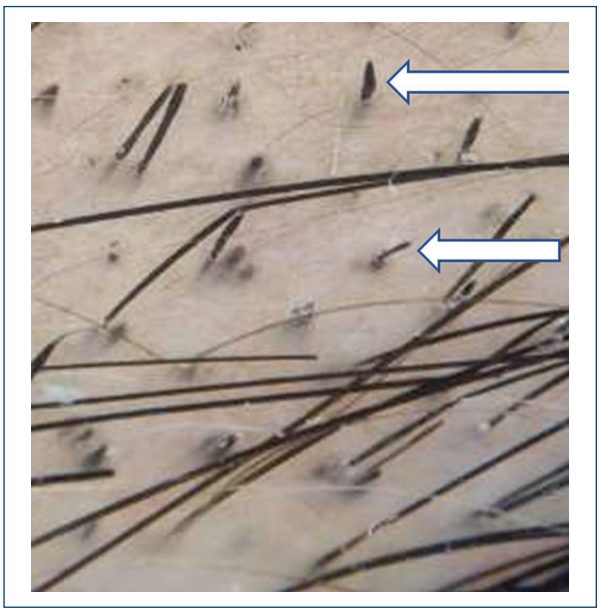

Figure 2. Broken hair.

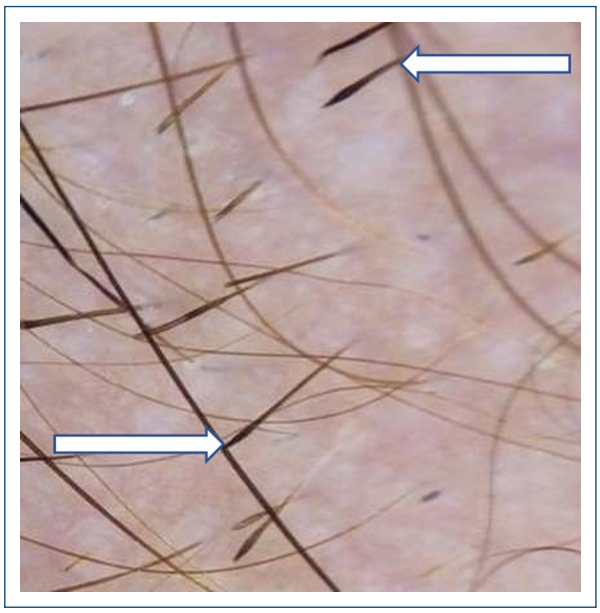

Figure 4. Showing Tapering hair.

of 1.7%[3]. It is characterized as a non-scarring form of hair loss involving the scalp and/or body without any clinical inflammatory signs. AA typically presents with well-defined, regular, circumscribed patches of hair loss with hair broken at equal length[4].

TTM is another form of non-scarring alopecia resembling AA. The disorder most commonly affects children between the age group of 9-13 years with female preponderance[1]. The scalp is the most common site, but it can also involve eyebrows, eyelashes, facial hair, axillary and pubic hair[5]. Clinically, patients present with irregular localized patches of hair loss with broken hairs of varying lengths, mainly in the frontoparietal area and the vertex[6].

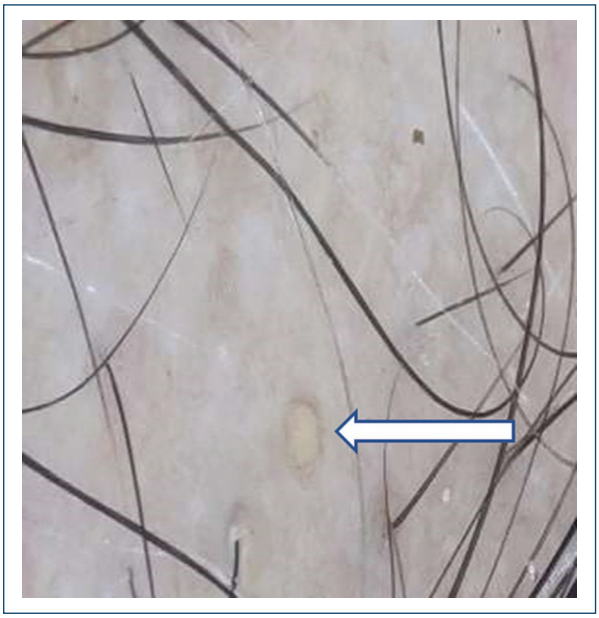

Figure 5. Yellow dots.

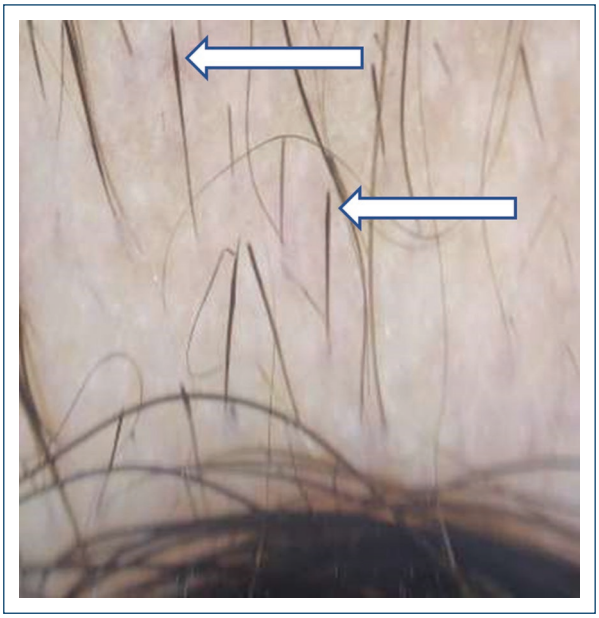

Figure 7. Tulip hair.

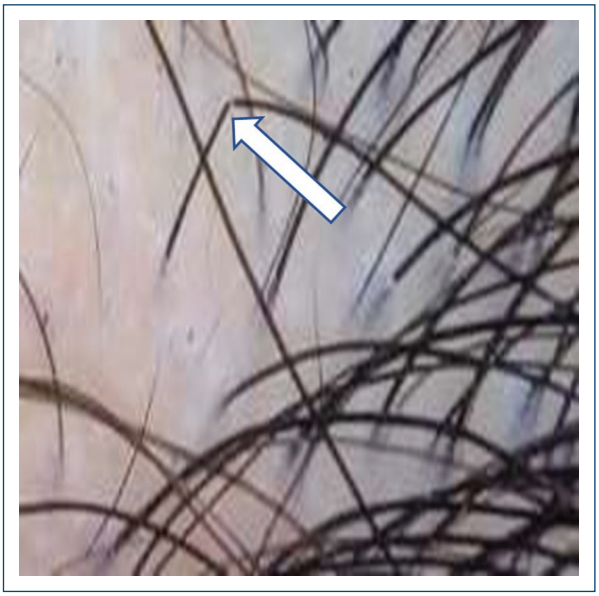

Figure 6. Coudability hair.

Figure 8. Trichoptilosis.

Diagnosis and treatment of these groups of disorders can be challenging. Even with careful clinical evaluation and proper history taking, the diagnosis can be missed. The diagnosis cannot be based per se on hair evaluation methods because of the variations in sensitivity and invasiveness of procedures, such as scalp biopsy, which are not frequently accepted by the patients[7]. So besides basic evaluation, it is important to have easy-to-use and non-invasive office tools such as dermatoscope that aid in performing the diagnosis and help to interpret the overlapping features of these hair disorders.

The diagnosis of AA cannot be made based on a single dermatoscopic feature but needs the combination of various dermatoscopic features. In our study, the combination of black dots, tapering hair, and broken hair was specific and diagnostic for AA. A similar trichoscopic



Figure 9. Broken hair at varying lengths.

Table 1. Trichoscopic features of alopecia areata (n = 76)

Trichoscopic features	No.	%
Black dots	51	67.11
Yellow dots	23	30.26
Tapering hair	27	35.53
Broken hair	50	65.79
Short vellus hair	36	47.37
Pigtail hair	18	23.68
Coudability hair	16	21.05
Tulip hair	8	10.52
Upright regrowing hair	6	7.89
Split ends	4	5.26

Figure 10. Coiled hair.

Table 2. Trichoscopic features of trichotillomania (n = 10)

Trichoscopic features	No.	%
Black dots	9	90.00
Tapering hair	1	10.00
Broken hair	10	100.00
Upright regrowing hair	7	70.00
Hair of varying lengths	10	100.00
Split ends	7	70.00
Coiled hair	7	70.00
Tulip hair	3	30.00
V sign	4	40.00
Flame hair	4	40.00

picture can also be seen in TTM with different characteristics of broken hair and black dots. Furthermore, we reported that the V sign, coiled hair, and flame hair are exclusively seen in TTM.

Tapering hair (aka exclamation mark hair) is considered to be pathognomonic of AA and a marker of the disease activity[8]. In our study, tapering hair was more frequently observed in not only in AA patients but also in TTM with a statistically significant difference. Rakowska et al. also observed a higher number of patients with exclamation mark hair in AA (81%) as compared to TTM (16%)[6]. Rakowska et al. also demonstrated the comparison of tapering hair seen in AA and TTM. The tapering hair in TTM has a flat distal end with a pigmented proximal end, whereas the tapering hair in AA has a frayed and uneven distal end with a hypopigmented proximal end[6].

We observed a statistically significant difference in the occurrence of black dots in patients of AA and TTM, with a higher number of black dots in AA patients, in agreement with the findings of Chiramel et al.[9], Rakowska et al. observed that black dots in AA are of

Table 3. Trichoscopic features of alopecia areata and trichotillomania

Trichoscopic features	Alopecia areata (n = 76)		Trichotillomania (n = 10)		r	p-value
	No.	% age	No.	% age		
Black dots	51	67.11	9	90	0.48	0.046*
Broken hair	50	65.9	10	100	0.37	0.044*
Tapering hair	27	35.53	1	10	0.43	0.034*
Tulip hair	8	10.52	3	30	0.42	0.035*
Split ends	4	5.26	7	70	1.00	0.000
Upright regrowing hair	6	7.89	7	70	1.00	0.000

*Significant at 0.05 level of significance.



Figure 11. V sign.



Figure 12. Flame hair.

uniform size and shape whereas in TTM, they are of variable diameter and shape[6].

Broken hair is formed due to the breakage of hair shafts at a different distance from the scalp surface. Ankad et al. in a study with 10 TTM patients observed broken hairs of varying lengths in 100% of patients[10], similar to our findings and to the study of Chiramel et al.[9]. Broken hair occurs both in AA and TTM, but in TTM, broken hairs typically have varying lengths[10].

In our study, we observed that patients with split ends, tulip hair, and upright regrowing hair were higher in TTM as compared to AA. This difference was statistically significant and similar to the findings of Rakowska et al.[6].

Upright regrowing hair is short hair with a tapered distal end and thickened proximal end[11]. We observed upright regrowing hair in 70% of patients of TTM, comparable to the study of Ankad et al. where upright regrowing hair was observed in 80% of patients[10].

Trichoptilosis refers to irregular hair with split ends. TTM is characterized by trichoptilosis affecting short hair[12]. Split ends were seen in 70% of TTM patients in our study, which was consistent with the findings of Chiramel et al.[9].

Flame hair, coiled hair, and V-sign were only seen in TTM in our study and thus were considered to be the specific features of TTM. Similar observations have been reported by Ankad et al.[10].

Flame hair refers to semi-transparent, wavy cone-shaped hair residues formed due to repetitive mechanical pulling of hair[11]. We reported flame hair in 40% of

TTM patients, findings comparable to Ankad et al. where flame hair was seen in 30% of patients[10]. Rakowska et al. and Govindarajaulu SM reported flame hair in a lower percentage, respectively, 25% and 20% of patients[6,8].

Coiled hair is formed as a result of hair shaft fracture and curling of the proximal part which remains attached to the scalp[13]. We observed coiled hair in 70% of patients of TTM which was comparable to the study of Ankad et al.[10].

V sign is formed when two or more hair emerges from a single follicular opening breaking at the same length above the scalp surface[11]. In our study, the V sign was seen in 40% of TTM patients, a percentage similar to Ankad et al. (30%)[10]. Nevertheless, other studies reported a higher incidence of V sign, namely Govindarajaulu et al. (100% of pati) and Chiramel et al. observed V sign in 80% of patients[8,9].

Trichoscopy has proved to be a reliable tool in the diagnosis of TTM by demonstrating distinctive dermatoscopic patterns and thus allows us to differentiate TTM from patchy AA[14]. Since TTM as a disease carries its social implications, early diagnosis and treatment are necessary. Dermatoscopy thus plays a vital role in the diagnosis of the disease and precludes the need for a scalp biopsy.

Conclusion

The early diagnosis using a dermatoscope helps in the timely management of non-scarring hair disorder and prevents the progression to cicatricial hair loss. Thus, the use of dermatoscopy in the clinical evaluation of these non-cicatricial alopecias enhances the diagnostic potential beyond the simple clinical examination. The combination of black dots, tapering hair, and broken hair is specific and diagnostic for AA. Broken hair at varying lengths, the V sign, coiled hair, and flame hair favors the diagnosis of TTM.

Funding

None.

Conflicts of interest

None.

Ethical disclosures

Protection of human and animal subjects. The authors declare that no experiments were performed on humans or animals for this study.

Confidentiality of data. The authors declare that they have followed the protocols of their work center on the publication of patient data.

Right to privacy and informed consent. The authors have obtained the written informed consent of the patients or subjects mentioned in the article. The corresponding author is in possession of this document.

Use of artificial intelligence for generating text. The authors declare that they have not used any type of generative artificial intelligence for the writing of this manuscript, nor for the creation of images, graphics, tables, or their corresponding captions.

References

1. Sah DE, Koo J, Price VH. Trichotillomania. Dermatol Ther. 2008;2:13-21.
2. McMichael AJ, Pearce DJ, Wasserman D, Camacho FT, Fleischer AB Jr., Feldman SR, et al. Alopecia in the United States: outpatient utilization and common prescribing patterns. J Am Acad Dermatol. 2007;Suppl 2:S49-51.
3. Tan E, Tay YK, Goh CL, Giam YC. The pattern and profile of alopecia areata in Singapore--a study of 219 Asians. Int J Dermatol. 2002;41:748-53.
4. Seetharam KA. Alopecia areata: an update. Indian J Dermatol Venereol Leprol. 2013;79:563-75.
5. Siddappa K. Trichotillomania. Indian J Dermatol Venereol Leprol. 2003;69:63-8.
6. Rakowska A, Slowinska M, Olszewska M, Rudnicka L. New trichoscopy findings in trichotillomania: flame hairs, V-sign, hook hairs, hair powder, tulip hairs. Acta Derm Venereol. 2014;94:303-6.
7. Romero JA, Grimalt R. Trichoscopy: essentials for the dermatologist. World J Dermatol. 2015;4:63-8.
8. Govindarajulu SM, Srinivas RT, Kuppuswamy SK, Prem P. Trichoscopic patterns of nonscarring alopecia's. Int J Trichology. 2020;12:99-106.
9. Chiramel MJ, Sharma VK, Khandpur S, Sreenivas V. Relevance of trichoscopy in the differential diagnosis of alopecia: a cross-sectional study from North India. Indian J Dermatol Venereol Leprol. 2016;82:651-8.
10. Ankad BS, Naidu MV, Beergouder SL, Sujana L. Trichoscopy in trichotillomania: a useful diagnostic tool. Int J Trichology. 2014;6:160-3.
11. Malakar S, Mehta PR, Mukherjee SS. Trichoscopy in pediatric age group. Indian J Paediatr Dermatol. 2018;19:93-101.
12. Rudnicka L, Olszewska M, Rakowska A, editors. Trichotillomania and traction alopecia. In: Atlas of Trichoscopy. Dermatoscopy in Hair and Scalp Disease. New York: Springer; 2012. p. 257-75.
13. Shukla D, Vishwanath T, Agrawal S, Dhurat R, Sharma A. A case of alopecia areata mimicking trichotillomania. Int J Dermoscop. 2017;1:35-7.
14. Khunkhet S, Vachiramon V, Suchonwanit P. Trichoscopic clues for diagnosis of alopecia areata and trichotillomania in Asians. Int J Dermatol. 2017;56:161-5.

Portuguese Journal of Dermatology and Venereology

Permanyer

Check for updates

Port J Dermatol and Venereol.

ORIGINAL ARTICLE

Home hospitalization for acute bacterial dermo-hypodermitis: seven years of experience

Hospitalização domiciliária na dermo-hipodermite aguda bacteriana: sete anos de experiência

José Ramos[1a], Sandra Lucas[2], António Silva[1], Ana Monteiro[1], Diogo Cerejeira[3], Vitória Cunha[2], and João Alves[1]*

[1]Serviço de Dermatologia, Hospital Garcia de Orta, EPE, Almada; [2]Unidade Hospitalização Domiciliária, Hospital Garcia de Orta, EPE, Almada; [3]Serviço de Dermatologia, Hospital Pedro Hispano, EPE, Matosinhos. Portugal
[a]ORCID: 0009-0007-5362-1141

Abstract

Background: Home hospitalization (HH) is an alternative to conventional hospitalization, but literature data about bacterial skin infections treated in this setting is sparse. **Objectives:** The objective is to characterize the demographic and clinical features of the population admitted with acute bacterial dermo-hypodermitis (ABDH) in a HH unit; to evaluate if this model can be a safe alternative to hospital care; and to assess patients' global satisfaction regarding their HH experience. **Methods:** Retrospective analysis of clinical data related to episodes of ABDH admitted to the HH unit of our institution in 7 years (2015-2022). A phone questionnaire was then applied for the evaluation of patients' global satisfaction about HH. **Results:** We included 88 patients with a mean age of 66.6 years. Seventy-one (81%) were admitted directly from the emergency department and 16 (18%) from hospital wards. Forty-five (51%) had at least three associated comorbidities. Local complications occurred in 21 patients (24%) and systemic complications in 7 (8%). Eight patients (9%) were transferred back to hospital care during their HH and only 1 patient (1%) was readmitted after 3 months of discharge. The mean duration of HH was 13.8 days, and the mean duration of antibiotic treatment was 14.6 days. Regarding patients' satisfaction, 41 participants (84%) rated home care with the maximum grade of satisfaction. For the participants with previous hospital stays (n = 39), 27 (69%) preferred HH to in-hospital care. **Conclusion:** This study suggests that, even though the population with ABDH admitted to HH is aged and has a high prevalence of comorbidities, HH is a safe and effective alternative to hospital care in the case of stable disease. It seems also to be associated with high rates of patient' satisfaction.

Keywords: Acute bacterial dermo-hypodermitis. Home hospitalization. Safety. Complications. Patient satisfaction.

Resumo

Introdução: A hospitalização domiciliária permite a prestação de cuidados de nível hospitalar no domicílio dos doentes, mas a literatura sobre o tratamento de infeções cutâneas bacterianas neste regime é escassa. **Objetivos:** Descrever as características demográficas e clínicas da população internada com dermo-hipodermite bacteriana aguda em hospitalização domiciliária, avaliar se este modelo constitui uma alternativa segura ao internamento convencional e aferir o grau de satisfação dos doentes relativamente ao seu internamento domiciliário. **Métodos:** Análise retrospetiva de dados clínicos relativos a

***Correspondence:**
José Ramos
E-mail: jalramos@campus.ul.pt

Received: 06-07-2023
Accepted: 23-08-2023
DOI: 10.24875/PJDV.23000058

Available online: 19-09-2023
Port J Dermatol and Venereol. 2023;81(4):239-244
www.portuguesejournalofdermatology.com

episódios de dermo-hipodermite bacteriana aguda admitidos numa unidade hospitalização domiciliária durante sete anos (2015-2022), e aplicação de um questionário por via telefónica para avaliar o grau de satisfação dos doentes. **Resultados**: Foram incluídos 88 doentes com uma idade média de 66.6 anos. Setenta e um (81%) foram admitidos diretamente do serviço de urgência e 6 (18%) da enfermaria hospitalar. Quarenta e cinco (51%) tinham pelo menos 3 comorbilidades associadas. Complicações locais ocorreram em 21 (24%) doentes e complicações sistémicas em 7 (8%). Oito doentes (9%) necessitaram de ser transferidos para meio hospitalar, e apenas 1 (1%) foi readmitido 3 meses após a alta. A duração média do internamento domiciliário foi de 13.8 dias, e a duração média da antibioterapia foi de 14.6 dias. Relativamente à satisfação dos doentes, 41 (84%) avaliaram o internamento domiciliário com nota máxima. No que concerne aos doentes com internamento hospitalar prévio (n = 39), 27 (69%) preferiram o internamento domiciliário. **Conclusão**: Os resultados sugerem que apesar da população em estudo tenha uma média de idades elevada e uma elevada prevalência de comorbilidades, a hospitalização domiciliária é uma alternativa segura e eficaz para o tratamento de dermo-hipodermites bacterianas agudas estáveis. A tal acresce estar associada a elevados índices de satisfação dos doentes.

Palavras-chave: Dermo-hipodermite bacteriana aguda. Hospitalização domiciliária. Segurança. Complicações. Satisfação do doente.

Introduction

Population aging and the high prevalence of chronic diseases are increasing the occupancy of hospital beds, and alternatives to conventional hospitalization are needed.

Home hospitalization (HH) is an innovative health model that provides hospital-level care to hemodynamically stable patients with acute medical conditions inside their own residence[1,2]. However, certain geographic and social criteria need to be met so that home care can be provided safely: the patient must reside in the area of influence of the hospital, and if he is not able to perform the activities of daily living autonomously, there must be a permanent caregiver at home[3].

Advantages of this health model compared to conventional hospitalization include a reduction of nosocomial complications, higher patient satisfaction (likely related to patients' remaining in the comfort of their homes), lower economic costs, and ambulatory medication reconciliation[1,2,4].

Literature data about bacterial skin infections, namely acute bacterial dermo-hypodermitis (ABDH), treated at HH are sparse. This article aimed to describe the demographic and clinical features of these patients, to evaluate if this model can be a safe alternative to hospital care, and to assess patients' global satisfaction regarding their HH experience.

Methods

The first part of this work is a descriptive retrospective study based on the revision of clinical records in which patients admitted to our HH unit with the main diagnosis of ABDH were included in the period from November 16th, 2015, to November 16th, 2022. Exclusion criteria were patients with surgical site infections, hardware/line infections, and bite wounds as entry points. Several variables were studied: age, gender, origin of referral to HH, infection site, number of previous ABDH, the existence of an entry point, risk factors (lymphedema, obesity, and chronic venous insufficiency), comorbidities (arterial hypertension, dyslipidemia, diabetes mellitus, cardiac failure or structural cardiopathy, vascular peripheral disease, cerebrovascular disease, atrial fibrillation, active or treated neoplasia, chronic kidney disease, chronic obstructive pulmonary disease, anemia, gastrointestinal pathology, benign prostatic hyperplasia, thyroid pathology, and osteoarticular disease), oral antibiotic failure at admission, hospital care admission during HH, local infectious complications – blister, abscess, necrosis; systemic complications – bacteriemia, adverse drug reaction, decompensation of underlying disease, death; empiric antibiotic regime, duration; length of stay in HH and hospital care; readmission rate after 1 and 3 months of discharge.

For the second part, the study protocol consisted of a brief, structured phone questionnaire directed to all patients studied in the first part, applied in April 2023. All participants gave their oral consent before participating. The following questions and possible options were asked: (1) "What is your overall satisfaction regarding your HH stay?" – very bad, bad, neither bad nor good, good, and very good; (2) "In the case of a previous hospitalization stay, how do you compare the HH experience with the hospital stay?" – much worse, worse, neither better nor worse, better, much better.

Table 1. Demographic and clinical features of the study population and complications of ABDH admitted at the home hospitalization

	Patients (n = 88)
Age – mean ± SD (min, max)	66.6 ± 16.8 (20-91)
Distribution by age group – n (%)	
20-49	15 (17)
50-74	36 (41)
≥ 75	37 (42)
Gender – n (%)	
Female	38 (43)
Origin of referral – n (%)	
Emergency department	71 (81)
Hospital ward	16 (18)
Hospital consultation	1 (1)
Entry point (e.g., ulcer, tinea pedis or local trauma) – n (%)	46 (52)
Infection location – n (%)	
Lower limb	78 (89)
Upper limb	8 (9)
Face	1 (1)
Other	1 (1)
History of previous ABDH – n (%)	25 (28)
1 episode	14 (16)
≥ 2 episodes	11 (13)
Risk factors – n (%)	
Obesity	23 (26)
Chronic venous insufficiency	21 (24)
Lymphedema	4 (5)
Oral antibiotic failure at admission – n (%)	24 (27)
Antibiotic prophylaxis for ABDH at admission and after discharge – n (%)	1 (1) | 1 (1)
HH length of stay – mean ± SD (min, max), n days	13,8 ± 6,9 (4-44)
Hospital-care and HH – mean ± SD (min, max), n days	16,4 ± 11 (6-93)
Duration of antibiotic treatment – mean ± SD (min, max), n days	14,6 ± 8,7 (4-57)
Local complications – n (%)	21 (24)
Blisters	13 (15)
Abscess	6 (7)
Necrosis	2 (2)
Systemic complications – n (%)	7 (8)
Bacteriemia	2 (2)
Adverse drug reaction	1 (1)
Decompensation of underlying disease	4 (5)
Death	0 (0)

ABDH: acute bacterial dermo-hypodermitis; HH: home hospitalization; SD: standard deviation.

Results

Part I – Characterization of the sample study with ABDH admitted to HH

During the study period, 92 patients met the inclusion criteria, but only 88 were eligible (4 patients were excluded). Demographic, clinical features, and local and systemic complications of the study population are described in table 1. About half of the population studied (51%) had at least three comorbidities. Arterial hypertension (65%), dyslipidemia (36%), and diabetes mellitus (25%) were the most common (Fig. 1).

Table 2. Patients transferred back to hospital care during home hospitalization: 8 patients (9%). Number of home hospitalization patients: 88

Clinical reasons (7 patients)	ABDH complications (2)	– Abscess drainage in the operating room – Osteomyelitis complicated with bacteriemia Controlled infection after below-knee amputation
	Exclusion of local complications due to refractory pain (2)	
	Adverse drug reaction (1)	– Morbiliform drug eruption
	Underlying disease decompensation (2)	– Syncope – Atrial fibrillation with rapid ventricular response
Social motives (1 patient)	Caregiver unavailability (1)	

ABDH: acute bacterial dermo-hypodermitis.

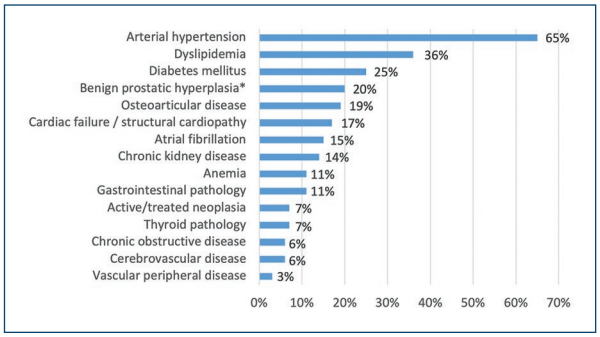

Figure 1. Comorbidities of the study population (n = 88). Arterial hypertension, dyslipidemia and diabetes mellitus are the most frequent.
*Percentage relative to male population.

During HH, 8 (9%) patients had to be transferred back to hospital care – 6 patients for clinical decompensation, 1 for surgical drainage, and 1 for social reasons (Table 2). Three patients returned to the HH soon after clinical stabilization.

Fifteen different empiric antibiotic regimens were used for the treatment of ABDH (Table 3): flucloxacillin (45%), intravenous, 4 times per day; ceftriaxone (18%), intravenous or intramuscular, once daily; and piperacillin-tazobactam (15%), intravenous, 3 times per day, were the most frequently chosen. Only one patient was treated with penicillin G, intravenous, 6 times per day. The average number of days of antibiotic therapy for ABHD was 14.6 ± 8.7.

Part II – Patients' global satisfaction regarding HH stay

From the 88 patients admitted to HH, we could only apply the phone questionnaire to 49: 10 patients had passed away, and 29 had unavailable phone numbers.

The median number of days between patients' HH and the phone questionnaire was 1262 (the minimum interval was 150 days and the maximum was 2643).

The results to the first question, "What is your overall satisfaction regarding your HH stay?" are presented in figure 2. Most participants (n = 41; 84%) rated HH with the maximum grade of satisfaction, and none classified it as "very bad" or "bad".

The second question focused on the comparison between patients' satisfaction with HH and conventional hospital stay. Ten participants had never had a previous hospital stay. The results are presented in figure 3: 27 participants (69%) preferred HH to hospital stay, and the rest (n = 12; 31%) had no preference between the two models.

Discussion

Compared to studies of inpatients with ABDH, the mean age of our population was higher than reported by Wojas-Pelc et al. and Roda et al. (63 and 61.2 years, respectively) and slightly inferior to that described by Batista et al. (68.6 years)[5-7]. As in previous studies, the prevalence was higher in males, and the lower limb was the most frequent site of infection[8,9]. The percentage of patients with previous ABDH was similar to that reported by Batista et al. (30.4%)[7].

Dupuy et al. found that local risk factors (e.g., toe web intertrigo) are the most important in the epidemiology of lower limb ABDH, and in our work, more than half of the patients had an identified portal of entry (Table 1)[10]. This data shows the importance of identifying and treating these factors in the prevention of ABDH.

The percentage of local complications was lower than described by Wojas-Pelc et al. in a retrospective analysis of 319 hospitalized patients with ABDH (25%) and higher than reported by Roda et al. (18%)[5,6]. Systemic complications

Table 3. Empiric antibiotic regimen for acute bacterial dermo-hypodermitis

	Patients (n = 88)
1st line empiric antibiotic regimen – n (%)	
Flucloxacillin	40 (45)
Ceftriaxone	16 (18)
Piperacillin-tazobactam	13 (15)
Clindamycin	4 (5)
Ceftriaxone + Clindamycin	3 (3)
Meropenem	2 (2)
Flucloxacillin + Penicillin	2 (2)
Imipenem + Cilastatin	1 (1)
Flucloxacillin + Amoxicillin-Clavulanate	1 (1)
Vancomycin + Flucloxacillin	1 (1)
Clindamycin + Penicillin	1 (1)
Clindamycin + Flucloxacillin	1 (1)
Amoxicillin-Clavulanate	1 (1)
Cefuroxime	1 (1)
Penicillin G	1 (1)
1st line empiric antibiotic failure – n (%)	6 (7)
Penicillin allergy – n (%)	3 (3)

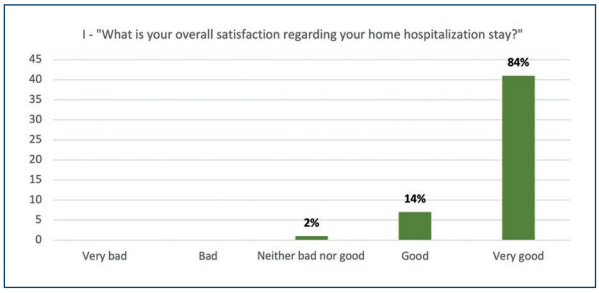

Figure 2. Phone questionnaire. Patients' global satisfaction regarding home hospitalization (n = 49). Results are shown in frequency (y-axis) and percentage.

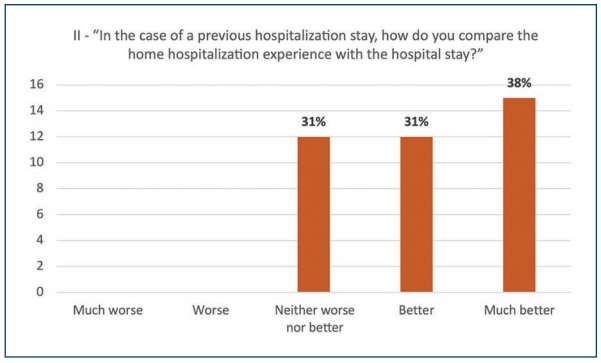

Figure 3. Phone questionnaire. Patients' comparison between home hospitalization experience versus previous conventional hospitalization (n = 39). Results are shown in absolute frequency (y-axis) and percentage.

such as bacteremia, adverse drug reaction and decompensation of underlying disease were identified in 8% of patients, a significant lower percentage than reported by a study with 102 patients hospitalized with ABDH (16%)[7]. These data can be explained by the higher clinical stability of ABDH patients admitted in home care. Only seven patients (8%) needed transfer to hospital care for clinical reasons, a lower percentage compared to a similar study with 101 patients with cellulitis treated with intravenous antibiotics at home, wherein 11 patients (12%) required hospital admission due to complications[11]. The low readmission rate 3 months after discharge (1%) is noteworthy. This data indicates that the HH team, in most cases, can address ABDH and its comorbidities effectively and safely.

The mean duration of antibiotic therapy, which already includes days of treatment after clinical discharge, was very similar to that reported by Batista et al. (14.5 days) and higher than other studies of inpatients with ABDH[7,10]. The prolongation of antibiotic therapy may have to do with the persistence of inflammatory signs in a later phase of ABDH, which is probably related to the local reaction of degradation products of the microorganism and tissue damage and not with persistent infection[7].

The mean length of stay (including home and hospital stays) was longer than that reported by Batista et al. (12.9 days) and Kozłowska et al. (11.6 days), both studies of ABDH treated in hospital, which could be explained by the overcrowding problem of conventional hospitalization and higher pressure to discharge[7,12]. Corwin et al., in a randomized controlled trial comparing intravenous antibiotic treatment for cellulitis at home versus in the hospital, did not find a significant difference in the number of days for discharge between the two groups of patients[11].

Only 1 patient (1%), who had 6 previous episodes of ABDH, was on prophylactic antibiotic therapy, a lower percentage than reported by Roda et al. (4%)[6]. We did not have access to the timing of this patients' previous ABDH episodes; however, it should be emphasized that in patients with recurrent episodes (3 or more per year) or with lymphedema, the initiation of prophylaxis with monthly intramuscular benzathine penicillin G should be considered[7].

The data suggest that our population is aged and has a high prevalence of comorbidities. Still, the percentage of systemic complications is similar to that of patients admitted to hospital care. On the other hand, whenever there is a serious clinical decompensation or when social or geographic criteria are no longer met, patients are immediately transferred to the hospital, ensuring their safety.

The participants showed an extraordinary rate of satisfaction regarding their HH experience. Most of the participants with previous hospital admissions preferred home care over hospital care; these results are in line with the existing evidence, where several studies (evolving medical conditions such as cellulitis, chronic heart failure and chronic obstructive pulmonary disease) reported increased patient satisfaction in the group treated at home[1,13,14]. These findings support further dissemination of the home care model.

The study has the limitations of a retrospective analysis, a reduced sample, and the absence of well-defined clinical criteria for the treatment of ABDH at HH. Regarding the limitations of the phone survey on patient satisfaction, we report the small size of the participants as well as the subjectivity of the questions. When comparing home and in-hospital care, satisfaction results may be influenced by the potential severity and instability of the medical condition that required conventional hospitalization.

Conclusion

This study suggests that, even though the population with ABDH admitted to HH is aged and has a high prevalence of comorbidities, HH is a safe and effective alternative for stable ABDH. It's not only a solution to the overcrowding problem of hospitals nowadays but also to reduce nosocomial complications and improve patient and family empowerment.

This work also corroborates the association between HH and high levels of patient' satisfaction.

Further studies are needed to identify clinical criteria to select the patients that will benefit the most from this alternative model of care.

Prizes and previous presentations

This study was presented in the "Spring Meeting of Portuguese Society of Dermatology and Venerology (2023)" and awarded with "Best Oral Communication".

Funding

None.

Conflicts of interest

None.

Ethical disclosures

Protection of human and animal subjects. The authors declare that no experiments were performed on humans or animals for this study.

Confidentiality of data. The authors declare that they have followed the protocols of their work center on the publication of patient data.

Right to privacy and informed consent. The authors have obtained approval from the Ethics Committee for analysis and publication of routinely acquired clinical data and informed consent was not required for this retrospective observational study.

Use of artificial intelligence for generating text. The authors declare that they have not used any type of generative artificial intelligence for the writing of this manuscript, nor for the creation of images, graphics, tables, or their corresponding captions.

References

1. Shepperd S, Iliffe S, Doll HA, Clarke MJ, Kalra L, Wilson AD, et al. Admission avoidance hospital at home. Cochrane Database Syst Rev. 2016;9:CD007491.
2. Cunha V, Escarigo MC, Correia J, Nortadas R, Azevedo PC, Beirão P, et al. Hospitalização domiciliária: balanço de um ano da primeira unidade Portuguesa. Rev Med Interna. 2017;24:290-5.
3. Direção Geral da Saúde. Hospitalização Domiciliária em Idade Adulta: Norma No 020/2018. Lisboa: DGS; 2018.
4. Delerue F, Correia J. Home hospitalization another challenge for internal medicine. Rev SPMI. 2018;25:15-7.
5. Wojas-Pelc A, Alekseenko A, Jaworek AK. Erysipelas--course of disease, recurrence, complications; a 10 years retrospective study. Przegl Epidemiol. 2007;61:457-64.
6. Roda Â, Pinto AM, Filipe AR, Travassos AR, Freitas JP, Filipe P. Clinical and laboratory factors associated with prolonged hospital stay among patients with cellulitis/erysipelas. Acta Med Port. 2019;32:448-52.
7. Batista M, Relvas M, Calado R, Brites MM, Gonçalo M. Uma revisão de dermohipodermite aguda bacteriana. J Portuguese Soc Dermatol Venereol. 2020;78:49-56.
8. Bjornsdottir S, Gottfredsson M, Thorisdottir AS, Gunnarsson GB, Ríkardsdóttir H, Kristjánsson M, et al. Risk factors for acute cellulitis of the lower limb: a prospective case-control study. Clin Infect Dis. 2005; 41:1416-22.
9. Kulthanan K, Rongrungruang Y, Siriporn A, Boonchai W, Suthipinittharm P, Sivayathorn A, et al. Clinical and microbiologic findings in cellulitis in Thai patients. J Med Assoc Thai. 1999;82:587-92.
10. Dupuy A, Benchikhi H, Roujeau JC, Bernard P, Vaillant L, Chosidow O, et al. Risk factors for erysipelas of the leg (cellulitis): case-control study. BMJ. 1999;318:1591-4.
11. Corwin P, Toop L, McGeoch G, Than M, Wynn-Thomas S, Wells JE, et al. Randomised controlled trial of intravenous antibiotic treatment for cellulitis at home compared with hospital. BMJ. 2005; 330:129.
12. Kozłowska D, Myśliwiec H, Kiluk P, Baran A, Milewska AJ, Flisiak I. Clinical and epidemiological assessment of patients hospitalized for primary and recurrent erysipelas. Przegl Epidemiol. 2016;70:575-84.
13. Gabel C, Ko LN, Dobry AS, Garza-Mayers AC, Milne LW, Nguyen E, et al. Patient preference for cellulitis treatment: at-home care is preferred to hospital-based treatment. J Am Acad Dermatol. 2021;85: 767-8.
14. Leff B, Burton L, Mader S, Naughton B, Burl J, Clark R, et al. Satisfaction with hospital at home care. J Am Geriatr Soc. 2006;54: 1355-63.

Portuguese Journal of Dermatology and Venereology

Permanyer

Check for updates

Port J Dermatol and Venereol.

ORIGINAL ARTICLE

Measurement of quality of life of vitiligo using disease-specific indicator and its association with area severity score

Medição da qualidade de vida do vitiligo usando indicador específico da doença e sua associação com o escore de gravidade da área

Guneet Awal[1a], Navleen Kaur[1], Guramrit Singh[1], and Amandeep Singh[2]*

[1]Department of Dermatology, Venereology and Leprosy; [2]Department of Radiology. Sri Guru Ram Das Institute of Medical Sciences and Research, Amritsar, Punjab, India
[a]ORCID: 0000-0003-0390-6142

Abstract

Background: Vitiligo is regarded as a psychosocial disorder for which assessment of disease severity is imperative to aid the management of disease. The association between demographic parameters, vitiligo severity, and quality of life (QoL) scores aids in gauging the impact of disease severity on QoL. **Objectives:** The aim of the study was to measure the QoL of vitiligo patients using vitiligo QoL (VitiQoL) index questionnaire and to assess its correlation with clinicodemographic patterns and vitiligo area severity index vitiligo area scoring index (VASI). **Methods:** One hundred and eight patients of vitiligo were included in this cross-sectional study. The disease severity was calculated using VASI score and patients were asked to fill the VitiQoL questionnaire (after translation to local language) for assessing the QOL. Demography, area severity, and QOL were statistically analyzed for demonstrating the correlation. **Results:** Statistically significant strong correlation was demonstrated between VitiQoL and VASI scores ($p = 0.001$; $r = 0.856$). In addition, female gender, young adults, lesions on exposed sites, and divorced status demonstrated significantly higher impact on the QOL than others ($p < 0.05$). **Conclusion:** QOL is significantly dependent on the disease severity and certain demographic patterns which reiterates the importance of measuring burden of vitiligo as a part of its multifaceted management.

Keywords: Vitiligo. VitiQoL. VASI. Quality of life.

Resumo

Introdução: O vitiligo é considerado um distúrbio psicossocial para o qual a avaliação da gravidade da doença é imperativa para auxiliar no manejo da doença. A associação entre parâmetros demográficos, gravidade do vitiligo e escores de qualidade de vida (QV) auxilia na mensuração do impacto da gravidade da doença na QV. **Objetivos:** Medir a QV de pacientes com vitiligo por meio do questionário vitiligo quality of life (VitiQoL) index e avaliar sua correlação com padrões clínico-demográficos e índice de gravidade da área de vitiligo (VASI). **Métodos:** 108 pacientes com vitiligo foram incluídos neste estudo transversal. A gravidade da doença foi calculada usando o escore VASI e os pacientes foram solicitados a preencher o questionário VitiQoL (após tradução para o idioma local) para avaliar a QV. Demografia, gravidade da área e QV foram analisadas estatisticamente para demonstrar a correlação. **Resultados:** Foi demonstrada forte correlação estatisticamente significativa entre os escores VitiQoL e VASI ($p = 0.001$; $r = 0.856$). Além disso, sexo feminino, adultos jovens, lesões em locais expostos e estado divorciado demonstraram impacto significativamente maior na QV do que outros (valor de $p < 0.05$).

***Correspondence:**
Guneet Awal
E-mail: guneetawal@gmail.com

Received: 10-08-2023
Accepted: 28-09-2023
DOI: 10.24875/PJDV.23000066

Available online: 20-12-2023
Port J Dermatol and Venereol. 2023;81(4):245-251
www.portuguesejournalofdermatology.com

Conclusão: A QV depende significativamente da gravidade da doença e de certos padrões demográficos, o que reitera a importância de medir a carga do vitiligo como parte do seu tratamento multifacetado.

Palavras-chave: Vitiligo. VitiQoL. VASI. Qualidade de vida.

Introduction

Vitiligo is a common disorder of pigmentation that can occur at any age and affects both genders nearly equally[1]. It is a multifactorial disorder having a complex pathogenesis for which multiple theories have been put forward, out of which the autoimmune theory is the most widely accepted[2]. Vitiligo can be classified as generalized, localized, segmental, or non-segmental. Rare clinical variants include trichrome, quadrichrome, pentachrome, red, and blue vitiligo[3]. The disease is usually slow and progressive having relapsing and remitting course along with exacerbations that might correlate with triggering events such as trauma (Koebner's phenomenon). Treatment of vitiligo remains challenging for a dermatologist despite the availability of various therapeutic modalities which makes it a cause of great psychosocial stress to the patients[4,5].

It is important to assess the severity of disease as it affects the psychological well-being of patients. The vitiligo area scoring index (VASI) is a quantitative score that uses hand units to quantify the proportion of vitiligo involvement[6]. Previously, there was no specialized quality of life (QOL) evaluation instrument for vitiligo; hence, it was assessed using non-disease specific scores[7-10]. Lately, evidence correlating vitiligo to various psychological issues proves it to be more of a psychosocial disorder affecting QOL, than merely a cosmetic concern[8,9,11,12]. Hence, a vitiligo-specific tool, vitiligo quality of life (VitiQoL), was developed[13]. It is an objective, vitiligo-specific assessment of disease state, burden, and treatment result for patients that is supported by disease-specific items derived from thorough open-ended patient interviews, clinician input, and a literature review[14].

In this study, we have attempted to use the vitiligo-specific questionnaire (VitiQoL) to sight impact of the disease on QOL among patients with diverse demographics.

Methods

The study was initiated after obtaining ethical clearance from the ethics committee of the institute. A total of 108 patients of vitiligo attending the department of dermatology in a tertiary care hospital were included in this cross-sectional, questionnaire-based study after obtaining informed consent. The study was conducted over a period of 2 years. The study population included clinically diagnosed cases of vitiligo above the age of 18 years. Dermoscopy was used to confirm the clinical diagnosis of the patients. Patients with other disorders and disabilities associated with social stigma were excluded from the study. A detailed history including the name, age, gender, marital status, occupation, duration, onset, progression, treatment history, and other relavant data was recorded. Thorough assessment covered skin type, region of involvement, and vitiligo type (acrofacial, segmental, focal, or universal). The severity of illness was determined by VASI scoring, and its relationship with VitiQoL scores was evaluated.

Study measurement tools

VASI score is a quantitative score used for the evaluation of the severity of vitiligo. The degree of residual depigmentation is expressed as: the depigmented area surpasses the pigmented area at 100% depigmentation; at 50% depigmentation, the depigmented and pigmented regions are equal; at 25% depigmentation, the pigmented area exceeds the depigmented area; and at 10% depigmentation, just specks of depigmentation are present[6]. VASI of each body site (hands, upper extremities, trunk, lower extremities, and feet) is calculated and then, cumulative body VASI is calculated using the following formula (range of 0-100):

VASI = Σ (all body sites) (hand units) × (residual depigmentation).

VitiQoL, proposed in 2013 by Lilly et al., is a disease-specific score used to measure concerns specific to the disease over a period of last month. It is based on three factors, namely, stigma, participation limitation, and behavior[14]. The score comprises 15 questions with a Likert scale of seven points (0-6) in which the total scores range from 0 to 90. Higher scores indicate a poorer QOL.

The English version of the VitiQoL questionnaire was translated into Punjabi language by a bilingual dermatologist. Backward translation of this questionnaire was done by another bilingual dermatologist and reviewed by the previous translator to ensure that

the questions conveyed the same meaning. The content validity of both the forward and backward translations was discussed by two evaluators who were experts in vitiligo and were also bilingual (fluent in English and also native Punjabi speakers). No questions were added or removed from the original version and score ratings also remained the same in the Punjabi version. Patients were then asked to fill the translated questionnaire for the assessment of the QOL. The Punjabi version of VitiQoL has been attached as a supplementary file.

Statistical analysis

Data were analyzed using Statistical Package for the Social Sciences (SPSS Inc., Chicago, IL, USA for Windows) version 26 software. Numbers and percentages were used to describe qualitative data. Descriptive statistics, mean, and standard deviation were calculated for the quantitative data. Pearson correlation coefficient was used for the assessment of the correlation between QOL score, that is, VitiQoL, and vitiligo severity score, that is, VASI. Independent t-test and analysis of variance (ANOVA) test was used for comparison of the demographic profile. Probability value $p < 0.05$ was considered as significant.

Results

The study enrolled 108 patients (53 females and 55 males), with a mean age of 39.89 ± 14.37 years. The disease was most commonly observed in the age group of 40-49 years (36.72%) with mean duration of 2.2 years from the beginning of lesions. Maximum number of patients belonged to Fitzpatrick skin type 4 (69.12%) followed by 3 (37.8%), and positive family history among first-degree relatives was seen in 29 patients (31.32%). According to the marital status of the patients, 48 were married whereas 53 were single and seven were divorced. The most prevalent occupational group observed was that of laborers (33.48%) followed by students (32.4%), household workers (24.84%), semi-skilled workers (15.12%), skilled workers (6.48%), and unemployed (4.32%). While 55.08% of patients had both exposed and non-exposed sites involved, 42.12% had lesions on non-exposed sites, and 19.44% on exposed sites only. The involvement of different sites in the study population is depicted in figure 1.

With regards to disease severity, mean VASI score in this study was 13.26 ± 9.12 and higher values were seen in patients with disease duration of < 3 years

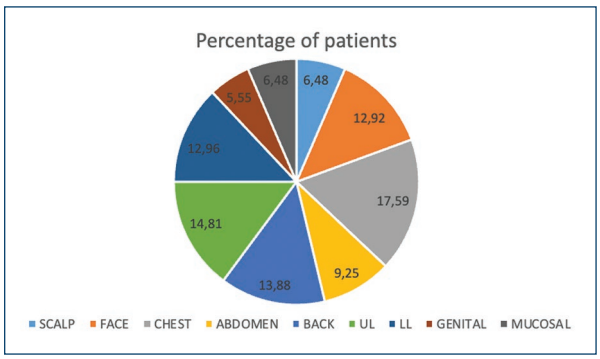

Figure 1. Involvement of various sites in the study population-scalp (6.48%), face (12.92%), chest (17.59%), abdomen (9.25%), back (13.88%), upper limb (14.81%), lower limb (12.96%), genital (5.55%), and mucosal (6.48%).

(15.06 ± 10.86), those who had positive family history among first-degree relatives (14.21 ± 11.48) and were unemployed (17.35 ± 2.26). Similarly, higher VASI scores were demonstrated among patients with skin type V (18.67 ± 12.92), had lesions on the exposed sites (14.17 ± 11.8), and had patches involving the lower limbs (17.43 ± 8.19). Mean VASI scores observed were almost alike in both genders (males: 13.49 ± 10.15; females: 13.02 ± 8.10). Similarly, nearly equal values of mean VASI were observed in patients of different marital status (divorced: 13.79 ± 3.90; single: 13.09 ± 9.47; married: 13.37 ± 9.48). Of all the above values obtained, none of these was statistically significant (Table 1).

Overall, the mean VitiQoL score of our study population was 25.71 ± 14.60, with statistically significant lower mean VitiQoL scores observed in males (24.53 ± 10.822) as compared to females (29.89 ± 12.57; $p = 0.019$). Similarly, higher statistically significant VitiQoL scores were observed in the age group of 18-29 years (31.64 ± 18.76; $p = 0.022$), who had lesions on the exposed sites (28.94 ± 12.25; $p = 0.039$) and among divorced patients (31.43 ± 11.60; $p = 0.019$). Higher scores were observed in patients with skin type V (33.67 ± 17.45), had lesions on the face (31.36 ± 21.82), and mucosal lesions (29.00 ± 16.62). The scores were highest in those who were unemployed (32.50 ± 25.56) and laborers (28.43 ± 16.10) as compared to other occupational groups, though not statistically significant (Table 2).

The highest mean VitiQoL score was seen in questions 1 and 9 of the questionnaire while the lowest mean scores were observed in questions 11 and 12. Similarly, the comparison of mean VitiQol scores among individual

Table 1. The correlation of VASI score with various demographic variables

VASI	n	VASI mean	Standard deviation of VASI
Gender			
F	53	13.02264	8.103042
M	55	13.49498	10.151652
Age			
18-29	29	13.35793	10.954816
30-39	23	12.92496	7.639786
40-49	34	11.76794	6.488887
50	22	15.80273	11.403364
Duration of disease			
< 3	46	15.06609	10.869080
3-6	25	12.64800	4.703092
7-12	18	8.33278	5.457519
13-15	7	13.36571	9.308494
> 15	12	14.96950	11.601466
Family history			
Positive	29	14.21034	11.487202
Negative	79	12.91549	8.208034
Marital status			
Divorce	7	13.79429	3.900576
Single	53	13.09566	9.470319
Married	48	13.37071	9.482691
Occupation			
Student	30	10.58347	6.152763
Labour	31	15.70290	9.655232
Household worker	23	13.90391	11.209264
Semiskilled	14	12.09071	4.175003
Skilled	6	11.61000	8.444875
Unemployed	4	17.35250	20.260318
Skin type			
Type III	35	13.12029	8.594867
Type IV	64	12.58006	8.766884
Type V	9	18.67667	12.929084
Sites			
Exposed	18	14.17056	11.800257
Covered	39	13.58615	8.785275
Exposed + covered	51	12.69596	8.543971
Individual sites			
Scalp	7	9.12700	3.541248
Face	14	12.85714	5.145439
Chest	19	13.30158	8.977349
Abdomen	10	17.24286	4.121850
Back	15	14.81067	7.569624
UL	16	9.61900	4.296506
LL	14	17.43571	8.193508
Genital	6	12.82167	7.023351
Mucosal	7	12.94714	7.334989

VASI: vitiligo area severity index.

domains of the questionnaire demonstrated higher values among "limited social participation" and "stigma" domain in the female gender and in the patients aged 18-29 years, while higher values among the questions pertaining to the "behaviour" domain were observed in patients with skin type V and in those who had lesions on the exposed sites (Table 3).

Figure 2 demonstrates the correlation of VASI score (13.26 ± 9.12) with VitiQoL score (25.71 ± 14.60) in which a very strong correlation was found between the two scores ($r = 0.856$ and $p < 0.001$).

Discussion

As a consequence of the high prevalence of vitiligo among various global races and the social stigma attached with it even among people of high economic status, there is an overwhelming impact on QoL and psychosocial component in the patients suffering from the disease. Despite the fact that India has the highest prevalence of the disease, there is a paucity of studies on the association of QoL indicators in vitiligo with disease activity and area scores in Indian patients[15]. In this particular study, though there was no significant difference among the mean VASI scores between males and females, the mean VitiQoL scores were significantly higher among females as compared to males, statistically ($p < 0.05$). This is similar to an earlier study done by Hedayat et al.[13] thereby implicating that the disease has more influence on the QoL in females. However, it is in contrast to previous studies which demonstrated that the psychological impact of the disease remains the same irrespective of the gender[16-18]. This contradiction can be attributed to the cultural variations among individuals belonging to different regions in which the studies were carried out.

Similarly, other demographic variables that demonstrated such statistically significant higher VitiQoL scores, and thus, poor QOL due to vitiligo, were individuals in the age group of 18-29 years, divorced patients, and those who had patches on the exposed body parts. All these before mentioned results were consistent with studies done prior on QOL in vitiligo using other scores[7,8,14,19].

The appearance of patches has been reported as grounds for divorce in many individuals as in our study[20,21]. Contrarily, in a study, conducted by in Saudi[22], the QOL of married people was affected as much as that of single individuals. This difference could be explained by the firm and false belief about the contagious nature of the disease in developing countries like India due to lack of education. This fact is further supported by the higher values of VitiQoL score obtained in unemployed patients and laborers as

Table 2. The correlation of vitiligo quality of life score with various demographic variables

VitiQoL	n	VitiQoL mean	Standard deviation of VitiQoL	p-value
Gender				
F	53	25.53	13.827	0.899
M	55	25.89	15.576	
Age				
18-29	29	25.52	16.311	0.181
30-39	23	23.87	12.282	
40-49	34	23.29	10.777	
> 50	22	31.64	18.766	
Duration of disease				
< 3	46	28.39	16.420	0.104
3-6	25	24.40	12.261	
7-12	18	18.06	8.235	
13-15	7	25.29	18.373	
> 15	12	29.92	15.030	
Family history				
Positive	29	26.45	16.832	0.754
Negative	79	25.44	13.910	
Marital status				
Divorce	7	29.43	11.603	0.762
Single	53	25.83	15.188	
Married	48	25.04	14.677	
Occupation				
Student	30	22.90	12.775	0.485
Labour	31	28.32	16.109	
Household worker	23	27.17	17.536	
Semiskilled	14	24.50	7.003	
Skilled	6	19.00	6.197	
Unemployed	4	32.50	25.567	
Skin type				
Type III	35	26.31	16.403	0.191
Type IV	64	24.27	13.061	
Type V	9	33.67	17.450	
Sites				
Exposed	18	25.94	17.254	0.983
Covered	39	25.97	15.399	
Exposed + covered	51	25.43	13.391	
Individual sites				
Scalp	7	27.14	20.416	0.192
Face	14	31.36	21.823	
Chest	19	28.00	14.380	
Abdomen	10	20.10	9.386	
Back	15	28.00	13.867	
UL	16	18.25	5.859	
LL	14	28.14	13.917	
Genital	6	17.67	3.615	
Mucosal	7	29.00	16.623	

VitiQoL: vitiligo quality of life.

compared to skilled individuals, though not statistically significant.

Overall, the mean VitiQoL scores were higher in questions 1 and 9, and lowest in questions 11 and 12 of the questionnaire, thereby indicating the fear of facing the society due to massive psychological impact on the diseased individuals. Among individual domains of VitiQoL questionnaire, the females and patients aged 18-29 years were found to have more limited social participation and stigma associated with the disease. On the other hand, the behavior domain was more affected in individuals who had skin type V and those having lesions

Table 3. The effect of various variables on individual domains of vitiligo quality of life questionnaire

Variables	Limited social participation		Stigma		Behavior	
	Mean	SD	Mean	SD	Mean	SD
Sex						
Male	3.58	1.72	4.63	1.36	3.95	1.91
Female	4.12	1.41	4.96	1.28	3.29	1.40
Age						
18-29	3.17	1.23	4.12	1.75	3.11	2.03
30-39	2.83	1.84	3.90	1.97	2.74	1.06
40-49	2.42	2.92	3.47	1.03	3.29	1.73
> 50	2.85	1.05	3.92	1.39	3.30	1.29
Skin colour						
III	3.68	2.95	2.83	1.95	3.15	2.01
IV	3.03	2.04	2.85	2.53	3.92	2.28
V	3.62	1.94	2.79	1.73	4.13	1.53
Patches exposure						
Exposed	3.72	1.92	2.90	1.39	3.60	1.74
Non-exposed	3.38	1.06	3.15	1.03	3.14	1.05
Both	3.94	2.02	3.07	1.86	3.36	1.96

SD: standard deviation.

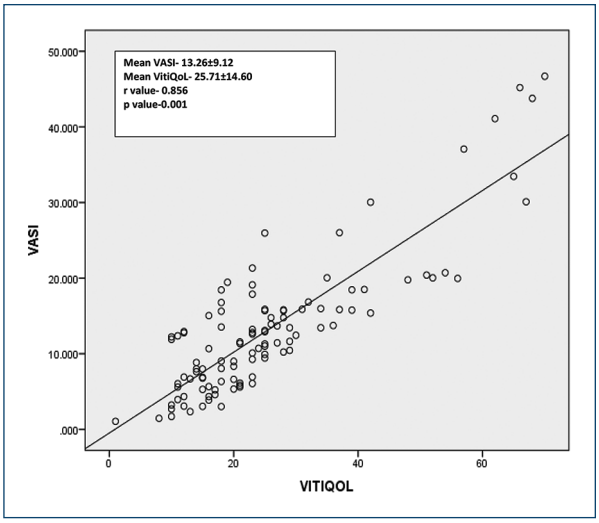

Figure 2. Scatter plot demonstrating the correlation between vitiligo area severity index score and vitiligo quality of life score; association of the parameters is shown by solid line (p = 0.001; r = 0.856).

on the exposed sites only. It is worth mentioning that the present study's greater participation limitation scores contradict the majority of previous researches[13,19,23]. This disparity in participation limitation might be due to increased aesthetic expectations from women and those in the young age, which make these individuals unable to carry out day-to-day and recreational endeavors as freely as other individuals due to the superstitions associated with the disease. This inability to interact with others leads to solitude, overthinking, concern, embarrassment, and humiliation which adds to the stigma associated with the disease. In a similar manner, this relatively poor QoL in skin Type V and in the individuals having lesions on the exposed sites can be explained by the societal pressure of age old beauty standards that forces these affected persons to resort to techniques of camouflage to hide their patches, which in turn, leads to emotional breakdown and behavioral alterations[13,19,23-25].

Furthermore, in the present study, it was observed that VitiQoL score had a statistically significant strong correlation with VASI score ($p < 0.001$, $r = 0.856$), which strikingly implies that higher the disease severity, more the impact on QoL. Several studies done before the present study have demonstrated this association of QoL scores with area severity scores[10,13,16,17] but none of this showed such a remarkably strong correlation between these two variables.

Limitations

The study was a based on the questionnaire and did not include any control group. Another limitation of the study is the lack of psychiatric evaluation, such as inclusion of anxiety and depression scores. Moreover, it was conducted in a hospital and hence, extrapolating this data to the community level may not be reflective of the real burden of the disease.

Conclusion

Despite several limitations, our study demonstrated association of the body surface area score (VASI) of vitiligo with disease-specific QoL score (VitiQoL). The study highlights the efficacy and superiority of vitiligo-specific QoL measures over previous scores which lacked disease-specific parameters, thereby emphasizing the importance of assessment and timely screening of patients of vitiligo for psychological impairment with the help of such questionnaires as it as essential part of disease management.

Supplementary data

Supplementary data are available at DOI: 10.24875/PJDV.23000066. These data are provided by the corresponding author and published online for the benefit of the reader. The contents of supplementary data are the sole responsibility of the authors.

Funding

None.

Conflicts of interest

None.

Ethical disclosures

Protection of human and animal subjects. The authors declare that no experiments were performed on humans or animals for this study.

Confidentiality of data. The authors declare that no patient data appear in this article.

Right to privacy and informed consent. The authors declare that no patient data appear in this article.

Use of artificial intelligence for generating text. The authors declare that they have not used any type of generative artificial intelligence for the writing of this manuscript nor for the creation of images, graphics, tables, or their corresponding captions.

References

1. Lapeere H, Boone B, De Schepper S, Verhaeghe E, Van Geel M, Ongenae K, et al. Hypomelanoses and hypermelanoses. In: Freedberg IM, Eisen AZ, Wolff K, Austen KF, Goldsmith LA, Katz SI, editors. Fitzpatrick's Dermatology in General Medicine. 6th ed. New York, USA: McGraw-Hill; 2003. p. 839-46.
2. Rashighi M, Harris JE. Vitiligo pathogenesis and emerging treatments. Dermatol Clin. 2017;35:257-65.
3. Mosher DB, Fitzpatrick TB, Ortonne JP, Hori Y. Hypomelanosis and hypermelanosis. In: Freedberg IM, Eisen Z, Wolff, K. Austen KF, Goldsmith LA, Katz SI, et al, editors. Fitzpatrick's Dermatology in General Medicine. 5th ed. New York, USA: McGraw-Hill; 1999. p. 949.
4. Malhotra N, Dytoc M. The pathogenesis of vitiligo. J Cutan Med Surg. 2013;17:153-72.
5. Njoo MD, Westerhof W. Vitiligo. Pathogenesis and treatment. Am J Clin Dermatol. 2001;2:167-81.
6. Hamzavi I, Jain H, McLean D, Shapiro J, Zeng H, Lui H. Parametric modeling of narrowband UV-B phototherapy for vitiligo using a novel quantitative tool: the vitiligo area scoring index. Arch Dermatol. 2004;140:677-83.
7. Parsad D, Dogra S, Kanwar AJ. Quality of life in patients with vitiligo. Health Qual Life Outcomes. 2003;1:58.
8. Mattoo SK, Handa S, Kaur I, Gupta N, Malhotra R. Psychiatric morbidity in vitiligo: prevalence and correlates in India. J Eur Acad Dermatol Venereol. 2002;16:573-8.
9. Porter JR, Beuf AH, Lerner A, Nordlund J. Psychosocial effect of vitiligo: a comparison of vitiligo patients with "normal" control subjects, with psoriasis patients, and with patients with other pigmentary disorders. J Am Acad Dermatol. 1986;15:220-4.
10. Wang KY, Wang KH, Zhang ZP. Health-related quality of life and marital quality of vitiligo patients in China. J Eur Acad Dermatol Venereol. 2011;25:429-35.
11. Talsania N, Lamb B, Bewley A. Vitiligo is more than skin deep: a survey of members of the vitiligo society. Clin Exp Dermatol. 2010;35:736-9.
12. Kent G, Al-Abadie M. Factors affecting responses on dermatology life quality index items among vitiligo sufferers. Clin Exp Dermatol. 1996;21:330-3.
13. Hedayat K, Karbakhsh M, Ghiasi M, Goodarzi A, Fakour Y, Akbari Z, et al. Quality of life in patients with vitiligo: a cross-sectional study based on vitiligo quality of life index (VitiQoL). Health Qual Life Outcomes. 2016;14:86.
14. Lilly E, Lu PD, Borovicka JH, Victorson D, Kwasny MJ, West DP, et al. Development and validation of a vitiligo-specific quality-of-life instrument (VitiQoL). J Am Acad Dermatol. 2013;69:e11-8.
15. Agarwal S, Jain C, Shaafie HI, Khalid A, Singh A. Impact on quality of life of family members of vitiligo patients in North India: a cross-sectional study using family dermatology life quality index. Indian J Dermatol Venereol Leprol. 2021;87:869-72.
16. Patvekar MA, Deo KS, Verma S, Kothari P, Gupta A. Quality of life in vitiligo: relationship to clinical severity and demographic data. Pigment Int. 2017;4:104-8.
17. Kota RS, Vora RV, Varma JR, Kota SK, Patel TM, Ganjiwale J. Study on assessment of quality of life and depression in patients of vitiligo. Indian Dermatol Online J. 2019;10:153-7.
18. Aghaei S, Sodaifi M, Jafari P, Mazharinia N, Finlay AY. DLQI scores in vitiligo: reliability and validity of the persian version. BMC Dermatol. 2004;4:8.
19. Dolatshahi M, Ghazi P, Feizy V, Hemami MR. Life quality assessment among patients with vitiligo: comparison of married and single patients in Iran. Indian J Dermatol Venereol Leprol. 2008;74:700.
20. Radtke MA, Schäfer I, Gajur A, Langenbruch A, Augustin M. Willingness-to-pay and quality of life in patients with vitiligo. Br J Dermatol. 2009;161:134-9.
21. Alikhan A, Felsten LM, Daly M, Petronic-Rosic V. Vitiligo: a comprehensive overview Part I. Introduction, epidemiology, quality of life, diagnosis, differential diagnosis, associations, histopathology, etiology, and work-up. J Am Acad Dermatol. 2011;65:473-91.
22. Al-Mubarak L, Al-Mohanna H, Al-Issa A, Jabak M, Mulekar SV. Quality of life in Saudi vitiligo patients. J Cutan Aesthet Surg. 2011;4:33-7.
23. Do Bú, Emerson & Alexandre, Maria & Santos, Vitória. (2021). Quality of Life of People with Vitiligo: A Brazilian Exploratory Study. Revista de Psicologia da IMED. 13. 264-283. 10.18256/2175-5027.2021.v13i1.4236.
24. Do Bú EA, De Alexandre ME, Scardua A, de Araújo CR. Vitiligo as a psychosocial disease: apprehensions of patients imprinted by the white. Interface Comun Saúde Educ. 2018;22:481-91.
25. Simons RE, Zevy DL, Jafferany M. Psychodermatology of vitiligo: psychological impact and consequences. Dermatol Ther. 2020;33:e13418.

Portuguese Journal of Dermatology and Venereology

Permanyer

Check for updates

Port J Dermatol and Venereol.

ORIGINAL ARTICLE

Sporotrichosis: a case series from a reference center in the Amazon

Esporotricose: uma série de casos de um centro de referência na Amazônia

Jéssica P. Leal[a], Carla A. Pires[b], Amanda Gabay-Moreira[c], Guilherme M. Colli[d], Adriana A. Araujo[e], Camila R. Araújo[f], Fernanda A. Santos[g], Mioni T. Brito[h], Maria A. Santos[i], and Francisca R. Carneiro[j]*

Dermatology of Outpatient Clinic, Center for Biological and Health Sciences, University of the State of Pará, Belém-PA, Brazil

ORCID: [a]0000-0002-0533-1728; [b]0000-0002-0566-9921; [c]0000-0002-5542-4981; [d]0000-0001-7148-5218; [e]0000-0001-6194-8350; [f]0000-0003-2292-8152; [g]0000-0003-4895-9168; [h]0000-0001-8165-8629; [i]0000-0001-8606-6948; [j]0000-0001-6735-4004

Abstract

Background: Sporotrichosis is the most prevalent subcutaneous mycosis in Latin America, being considered endemic in the state of Pará, with high morbidity. **Objective:** The objective of the study is to analyze epidemiological data, characteristics, and clinical outcome of patients with sporotrichosis treated at a reference service in tropical dermatology in the Amazon region. **Methods:** Analysis of cases observed between 2020 and 2022, with a diagnosis confirmed by anatomopathological study and culture for sporotrichosis. Clinical data, evolution, and therapeutic approach were collected in the researchers' own protocol. **Results:** There were 7 patients with a female predominance (71.4%), average age of 32 years. 57% of the cases presented the lymphocutaneous form, and only 1 patient expressed the extracutaneous form. All patients used oral itraconazole, requiring the association of oral potassium iodide and amphotericin B eye drops for ocular sporotrichosis. The average treatment duration was 7 months and all cases resolved completely. **Conclusion:** Data allowed the analysis of clinical diversities, the therapeutic approach, and the clinical outcome. The importance of early diagnosis is emphasized, especially in endemic areas, to institute the most appropriate treatment, reducing the number of cases.

Keywords: Sporotrichosis. Cutaneous sporotrichosis. Lymphocutaneous sportothrichosis. Sporotrichosis epidemiology. Feline sporotrichosis. *Sporothrix brasiliensis.*

Resumo

Introdução: Esporotricose é a micose subcutânea mais prevalente na América Latina, sendo considerada endêmica no Estado do Pará, com elevada morbidade. **Objetivos:** Analisar dados epidemiológicos, características e desfecho clínico de pacientes com esporotricose observados num serviço de referência em dermatologia tropical na região Amazônica. **Métodos:** Descreve-se uma série de casos observados entre 2020 e 2022, com diagnóstico confirmado por estudo anatomopatológico e cultura para esporotricose. Os dados clínicos, evolução e abordagem terapêutica foram colhidos em protocolo próprio dos pesquisadores. **Resultados:** Foram analisados 7 pacientes, com predomínio do sexo feminino e média de 32 anos de idade. 57% dos casos apresentaram a forma linfocutâneas, apenas 1 paciente expressou a forma extracutânea. Todos pacientes utilizaram itraconazol, sendo necessário associação de iodeto de potássio via oral e anfotericina B colírio para a esporotricose ocular.

***Correspondence:**
Amanda Gabay-Moreira
E-mail: gabayamanda@gmail.com

Received: 10-08-2023
Accepted: 25-10-2023
DOI: 10.24875/PJDV.23000067

Available online: 20-12-2023
Port J Dermatol and Venereol. 2023;81(4):252-258
www.portuguesejournalofdermatology.com

O tempo médio de tratamento foi de 7 meses. Todos os pacientes evoluíram para a cura. **Conclusão:** Os dados permitiram a análise das diversidades clínicas, da abordagem terapêutica e do desfecho clínico. Ressalta-se a importância do diagnóstico precoce, especialmente, em áreas endêmicas, para instituir o tratamento mais adequado, reduzindo o número de casos quer exclusivamente cutâneos, quer a disseminação sistémica.

Palavras-chave: Esporotricose. Esporotricose subcutânea. Esporotricose linfocutânea. Epidemiologia da esporotricose. Esporotricose felina. *Sporothrix brasiliensis.*

Introduction

Sporotrichosis is a chronic subcutaneous or lymphocutaneous granulomatous infection[1], caused by thermodimorphic fungi of the genus *Sporothrix*[2]. The disease has a worldwide distribution, especially in tropical and subtropical areas, as temperature and humidity favor the spread of the fungus[3]. Its predominance in populations with a lower socioeconomic profile makes this pathology a candidate for inclusion in the World Health Organization list of Neglected Tropical Diseases[4] as a public health problem of extreme importance.

Sporotrichosis is the most prevalent subcutaneous mycosis in Latin America, still considered endemic in countries such as Brazil, Colombia, Venezuela, and Argentina[5]. Several Brazilian states have a particularly high incidence and compulsory notification of the disease, such as São Paulo, Pernambuco, and mainly, Rio de Janeiro[6], which was considered a hyperendemic region since 1998, and has been responsible for 32% of hospitalizations and 23% of deaths in recent decades[7].

There are two main routes of transmission of the disease to humans, after traumatic inoculation of the spores or mycelial fragments of the fungus into the dermis[4], either by direct contact with decomposing organic matter or infected soil, or by animal scratches, in which felines, especially cats are particularly important[5]. Since the 1990s, the latter route has shown a greater correlation with the increase in the number of severe cases in Brazil[2].

It is extremely important, therefore, to consider the epidemiological data, clinical characteristics, and outcome of patients with sporotrichosis, with the aim of reducing the number of cases, creating effective measures to promote health and prevent the disease, in addition to more appropriate and early therapy.

Methodology

This is a descriptive, observational, and single-center case series study, carried out at the dermatology service of the Center for Biological and Health Sciences at the University of the state of Pará, in Belém, Pará, one of the reference centers in secondary care for general and tropical dermatological diseases in the region. The research was carried out after approval by the University's Research Ethics Committee, opinion nº 5.647.696, and authorization from the coordination of the University's Dermatology Service.

This is a convenience sample and consists of patients with sporotrichosis treated in the years 2020-2022, with a positive epidemiological history (contact with a cat) and confirmed by anatomopathological examination and culture for fungi.

A standardized protocol authored by the researchers was used to collect data from the medical records. The variables collected were epidemiological data, clinical aspects of the lesions, type of treatment, and clinical outcome.

Results

Seven patients diagnosed with sporotrichosis were analyzed, five females and two males, with ages ranging from 10 to 53 years (mean 32 years) (Table 1). Four had no previous comorbidities, one had systemic arterial hypertension and type 2 diabetes mellitus (Case 1), one had severe mental retardation (Case 6), and one suffered from antiphospholipid syndrome (Case 7 - Fig. 1). Only one patient had contamination by fomites, while the others had direct inoculation through contaminated cat scratches, and only one feline died within a period of 3 months.

All patients presented ulcerated erythematous nodules at the beginning of the condition, four with a linear arrangement of nodules in the lymphatic path (Cases 1, 2, 5, and 7 - Fig. 2), and three had palpable painful lymphadenopathy with a fibroelastic consistency (Cases 1, 3 and 7). All patients were treated with itraconazole 100 mg, 2 pills a day for 4-12 months (average 7 months), depending on treatment response and complications during treatment.

Case 5 presented secondary bacterial infection in two different moments and needed additional antibiotic

Table 1. Epidemiological and clinical data of the 7 patients diagnosed with sporotrichosis in the period from 2020 to 2022 at the Dermatology Clinic

No	Sex	Age	Occupation	Comorbidities	Cutaneous lesions	Localization	Treatment
1	M	33	Teacher	AH, DM2	Ulcerated erythematous nodule (1 cm × 0.8 cm), linear infiltrated erythematous plaque (8 cm × 1.5 cm)	Left wrist Right leg	Itraconazole 200 mg/day 6 months
2	F	53	Home worker	-	Two erythematous nodules, one exulcerated with purulent discharge	Forearm and left first finger	Itraconazole 200 mg/day for 7 months
3	F	26	Occupational therapist	-	Erythematous nodule with an ulcerated center	3rd right finger	Itraconazole 200 mg/day for 4 months
4	F	42	Day laborer	-	Erythematous nodule with an ulcerated center	3rd right finger	Itraconazole 200 mg/day for 7 months
5	F	22	Veterinary	-	Discretely infiltrated erythematous edge ulceration with purulent background	Metacarpophalangeal area of the 1st left finger accompanied by erythematous nodules	Itraconazole 200 mg/day for 2 months Itraconazole 400 mg/day for 2 months Potassium iodide 3 mL/day for 3 months
6	M	10	Student	Severe mental retardation	Erythematous plaque with an ulcerated center covered by a serohematic crust with clear limits and regular contours measuring 1.0 cm × 1.5 cm	In the 1st right finger	Itraconazole 200 mg/day for 9 months
7	F	38	Administrator	Anti-phospholipid syndrome Under treatment with AAS 100 mg/day	Erythematous papules and nodules, some ulcerated, with regular contours and well-defined limits, ranging from 0.2 cm × 0.2 cm to 0.7 cm × 0.7 cm	In the upper limbs	Itraconazole 200 mg/day for 12 months Amphotericin B 0.15% eye drops every 3/3 h for 4 months

DM2: diabetes mellitus type 2; AS: antiphospholipid syndrome; M: male; F: female.

therapy. After this last episode, there was a progressive worsening of the sporotrichosis, requiring the association of itraconazole with potassium iodide 6 mg/day for 3 months.

Case 7, after 1 month of itraconazole 200 mg/day, complained of conjunctival hyperemia and blurred vision in the left eye, being diagnosed with ocular sporotrichosis. Amphotericin B 0.15% eye drops every 3 h for 4 months.

All 7 patients in the study progressed to cure, with complete resolution of the lesions, and all patients were still cleared after 1 year of follow-up after drug withdrawal.

Discussion

Sporotrichosis is the most common subcutaneous mycosis in the world, caused by dimorphic and geophilic fungi, of the species *Sporothrix* spp.[1], being considered endemic in tropical, subtropical, and temperate zones with hot and humid climate[3], such as the one in which the study was carried out, which favors the

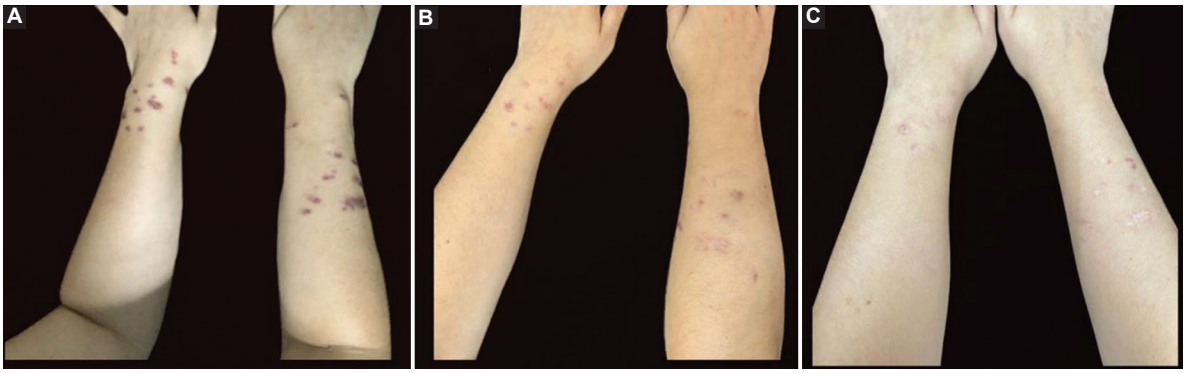

Figure 1. Cutaneous lesions in case 7. Erythematous papules and nodules, some with ulceration, with regular borders and well-defined limits, on the upper limbs, after using itraconazole for **A:** 2 months, **B:** 3 months, and **C:** 6 months.

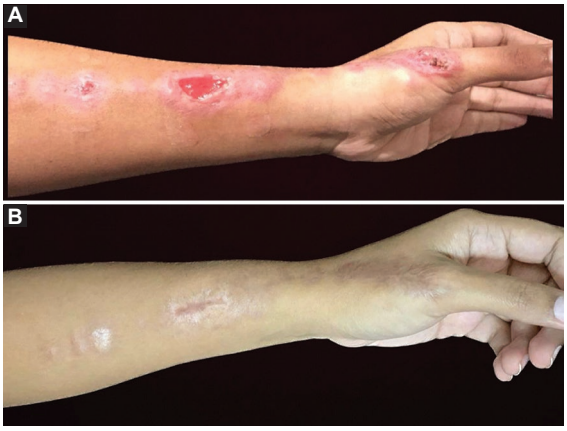

Figure 2. Cutaneous lesion in case 5. Erythematous nodules and plaques in a linear distribution with subsequent ulceration localized to the thumb and forearm. **A:** before starting treatment and **B:** 5 months after using itraconazole and potassium iodide.

growth of saprophytic fungi[8]. Sporotrichosis, although not a pathology with high morbidity, except in the disseminated forms, is responsible for great disability, directly affecting the quality of life of affected individuals[9], and is sometimes considered an occupational disease for groups of potential contamination[10].

The pathogen is usually found in the soil and plants, with the agent being inoculated into the skin or mucous membrane due to trauma, which is why it has been known as "gardener's mycosis" for a long time[6]. On the other hand, in Brazil, sporotrichosis is mainly due to zoonotic transmission, through the bite or scratches of felines contaminated with the fungus[11], usually *Sporothrix brasiliensis.* It is important to emphasize that most patients in the present study were contaminated in this way, corroborating with the current literature. No age group or sex is spared from this infection, given that its occurrence depends on the fungus in the environment and the inoculation point, however, a higher frequency of occurrence in males is noted, being attributed to their greater risk of exposure to the pathogen[8]. This male predominance was not observed in this current study (only two male patients) probably explained by the frequent transmission by cats.

As for the pathogenesis, the cell wall of the pathogen induces an innate immune response, especially from *S. brasiliensis*, and the host reacts through a humoral and cell-mediated reaction, with CD4+ T cells with a mixed Th1 and Th17 immune response, capable of stimulating the secretion of cytokines such as interferon-gamma, tumor necrosis factor-alpha, and interleukin-17a, which, in turn, activate macrophages and neutrophils for fungal elimination[12,13]. The variability of response depends both on the factors related to the parasite itself and the immunoinflammatory capacities of the host and may explain the great clinical variability of the disease, dividing it into two large groups: cutaneous and extracutaneous, the first of which is subdivided into lymphocutaneous and fixed cutaneous[14]. The type of immune response is of paramount importance, as in this study, the extracutaneous form occurred in a patient with active autoimmune disease under treatment with acetylsalicylic acid 100 mg/day, which may have interfered with the immune response.

Incubation period remains uncertain, ranging from days to months, with an average of 3 weeks[15].

Cutaneous lesions progressively develop in the form of papules or nodules, and the site of inoculation can ulcerate, characterizing the fixed form of cutaneous sporotrichosis[6]. However, up to 4 weeks after the trauma, multiple painless nodules can develop along the lymphatic vessels, usually in the hands and lower limbs, characterizing lymphocutaneous sporotrichosis[7], responsible for approximately 80% of cases[6]. Lesions can increase in size, become verrucous, nodular, or ulcerated, known as "sporotrichotic cancer"[6] and in addition, lesions often extend to the lymphatics and these satellite lymph nodes can ulcerate and form fistulas as well[16]. More than half of the patients in this study expressed this lymphocutaneous clinical form, confirming literature findings.

Due to the diversity of clinical presentations, sporotrichosis may be clinically similar to cutaneous tuberculosis, American mucocutaneous leishmaniasis, chromoblastomycosis, paracoccidioidomycosis[15], in addition to pyoderma gangrenosum and cat scratch disease[6].

Disseminated or hematogenous sporotrichosis is rare and usually occurs in severely immunocompromised patients[9], such as alcoholism, diabetes, acquired immunodeficiency syndrome, paraneoplastic syndromes, and use of immunosuppressive drugs[15]. It can affect several organs and systems, such as central nervous system, osteoarticular, ocular, and pulmonary[17]. Among the extracutaneous manifestations, the ocular mucosa is most commonly affected[6], as the only extracutaneous form described in the study. Anatomical criteria and the source of infection explain this localization, which presents either as an adnexal infection, affecting eyelid, conjunctiva and lacrimal sac, or an intraocular infection[18], with exogenous or endogenous endophthalmitis. Among ocular lesions, 82% are limited to the eyelids, mainly caused by *Sporothrix schenckii, S. brasiliensis,* and *Sporothrix globosa*[19], predominantly affect children, with a history of trauma by plant material and wood[20]. Eyelid lesions can be primary or due to lymphocutaneous lesions from hematogenous dissemination, presenting as papules or ulcerated nodules[19]. There is also conjunctival sporotrichosis, with most cases reported in the current literature in Brazil, where no previous trauma was reported, although contact with cats has been reported in 90% of patients[18], like the 7th case of this series. This situation can mimic several infectious or non-infectious diseases, and it is necessary to confirm the diagnosis through mycological examination[20].

The gold standard for the diagnosis is based on biopsy, aspirates from abscesses, sputum, blood, synovial, and cerebrospinal fluid, based on the isolation and identification of Sporothrix species in culture and polymerase chain reaction[15]. Direct microscopy has low sensitivity and specificity in humans, presenting the "cigar-shaped" pattern, usually in immunosuppressed individuals[21], however, this method is very sensitive in animals[6]. All patients had diagnostic confirmation both by biopsy with histopathological study and culture. The Splendore-Hoeppli phenomenon (sulfur granules) in the histopathological examination may suggest a diagnosis of sporotrichosis, however, it is not specific, considering that it may be present in other granulomatous diseases[22]. Serology is usually reserved for the diagnosis of systemic or atypical forms, in addition to helping to monitor treatment and withdrawal of medications in more complex clinical presentations[12], not being used in this study for any of these purposes.

The therapeutic choice depends on the clinical form of the disease, the immune status of the host, and the species involved[23]. At present, in Brazil, the drugs available are itraconazole, potassium iodine (KI), terbinafine, and amphotericin B[6]. Itraconazole, used in all patients in this series, is considered the medication of choice due to its efficacy, dosage convenience, and can be administered continuously or in pulses[24], from 100 mg to 400 mg/day, starting, preferably, with the minimum dose[25]. It should be emphasized that all azoles are contraindicated in pregnant women, and they inhibit cytochrome P450 and, therefore, drugs metabolized by this enzymatic system, such as warfarin, anticonvulsants, statins, and oral hypoglycemic agents are contraindicated[15], due to the drug interactions. Follow-up between 1 and 2 months with laboratory tests is advised.

KI is mostly used in countries with limited resources and in immunoreactive forms such as erythema nodosum or reactive arthritis, due to its immunomodulatory effect[4], which is why it was associated with itraconazole in a patient with an unsatisfactory response to monotherapy for 3 months. Terbinafine is indicated in the case of contraindication to the aforementioned drugs. As this drug is metabolized through CYP2D6, it presents fewer drug interactions[26] and is, therefore, useful in elderly patients or patients with multiple comorbidities. The recommended dose is 250 mg/day, which can be doubled in adults[6].

Amphotericin B is reserved for severe life-threatening cases and in pregnant women[27], with efficacy between

90% and 100%[26]. Topical amphotericin B for 4-12 months of treatment, alone or associated with an oral antifungal, is the treatment of choice in intraocular infections but requires continuous renal evaluation due to its nephrotoxic potential[18]. In case 7, amphotericin eye drops were used for 4 months to treat the conjunctival presentation.

Treatment should be maintained until clinical cure, that is, when there is no disease activity, with an average duration of 4 months[8]. In addition to drug treatment in humans, it is necessary to treat infected cats as well as to incinerate animals killed by the disease, to prevent the spread of the pathogen in the soil[6].

Conclusion

The present study provides demographic data, clinical characterization, and its diversities, in addition to the types of treatment used in medical practice in a reference center in northern Brazil, an endemic area of the disease. Data emphasize the importance of recognizing the clinical forms to enable early diagnosis and adequate treatment of sporotrichosis, as well as the notification of the disease to obtain a more reliable epidemiology, to reduce the number of disease cases and their morbidity.

Funding

None.

Conflicts of interest

None.

Ethical disclosures

Protection of human and animal subjects. The authors declare that the procedures followed were in accordance with the regulations of the relevant clinical research ethics committee and with those of the Code of Ethics of the World Medical Association (Declaration of Helsinki).

Confidentiality of data. The authors declare that they have followed the protocols of their work center on the publication of patient data.

Right to privacy and informed consent. The authors have obtained approval from the Ethics Committee for analysis and publication of routinely acquired clinical data and informed consent was not required for this retrospective observational study.

Use of artificial intelligence for generating text. The authors declare that they have not used any type of generative artificial intelligence for the writing of this manuscript, nor for the creation of images, graphics, tables, or their corresponding captions.

References

1. Sharma R, Mahajan VK, Singh Chauhan P, Mehta KS, Sharma A, Sharma J. The clinico-epidemiological characteristics and therapeutic experience of 152 patients with cutaneous sporotrichosis: a 10-year retrospective study from India. Int J Dermatol. 2021;60:99-106.
2. Lecca LO, Paiva MT, de Oliveira CS, Morais MH, de Azevedo MI, Bastos CV, et al. Associated factors and spatial patterns of the epidemic sporotrichosis in a high density human populated area: a cross-sectional study from 2016 to 2018. Prev Vet Med. 2020;176:104939.
3. Benvegnú AM, Dallazzem LN, Chemello RM, Beber AA, Chemello D. Case series of sporotrichosis at a teaching hospital in Brazil. Rev Soc Bras Med Trop. 2020;53:e20190509.
4. Rasamoelina T, Raharolahy O, Rakotozandrindrainy N, Ranaivo I, Andrianarison M, Rakotonirina B, et al. Chromoblastomycosis and sporotrichosis, two endemic but neglected fungal infections in Madagascar. J Mycol Med. 2017;27:312-24.
5. Caus AL, Zanotti RL, Faccini-Martínez ÁA, Paterlini GV, Falqueto A. Epidemiological and clinical aspects of sporotrichosis in Espírito Santo State, Southeast Brazil: a study of three decades (1982-2012). Am J Trop Med Hyg. 2019;100:706-13.
6. Orofino-Costa R, Macedo PM, Rodrigues AM, Bernardes-Engemann AR. Sporotrichosis: an update on epidemiology, etiopathogenesis, laboratory and clinical therapeutics. An Bras Dermatol. 2017;92:606-20.
7. Falcão EM, de Lima Filho JB, Campos DP, do Valle AC, Bastos FI, Gutierrez-Galhardo MC, et al. Hospitalizações e óbitos relacionados à esporotricose no Brasil (1992-2015). Cad Saúde Pública. 2019;35:e00109218.
8. Albuquerque PC, Fonseca BP, Zicker F, Zancopé-Oliveira RM, Almeida-Paes R. Bibliometric assessment and key messages of sporotrichosis research (1945-2018). F1000Res. 2020;9:654.
9. Estrada-Castañón R, Estrada-Chávez G, Chávez-López MG. Diagnosis and management of fungal neglected tropical diseases in community settings-mycetoma and sporotrichosis. Trop Med Infect Dis. 2019;4:81.
10. Conti Díaz IA. Epidemiology of sporotrichosis in Latin America. Mycopathologia. 1989;108:113-6.
11. Gameiro Filho AR, Estacia CT, Gameiro RR, de Mattos Fonseca Vieira L, Socci da Costa D. Ocular and cutaneous sporotrichosis. Am J Ophthalmol Case Rep. 2020;20:100885.
12. García Carnero LC, Lozoya Pérez NE, González Hernández SE, Martínez Álvarez JA. Immunity and treatment of sporotrichosis. J Fungi (Basel). 2018;4:100.
13. Rodrigues AM, Kubitschek-Barreira PH, Fernandes GF, de Almeida SR, Lopes-Bezerra LM, de Camargo ZP. Immunoproteomic analysis reveals a convergent humoral response signature in the *Sporothrix schenckii* complex. J Proteomics. 2015;115:8-22.
14. Tirado-Sánchez A, Bonifaz A. Nodular lymphangitis (sporotrichoid lymphocutaneous infections). Clues to differential diagnosis. J Fungi (Basel). 2018;4:56.
15. Mahajan VK. Sporotrichosis: an overview and therapeutic options. Dermatol Res Pract. 2014;2014:272376.
16. Lopes-Bezerra LM, Schubach A, Costa RO. *Sporothrix schenckii* and sporotrichosis. An Acad Bras Cienc. 2006;78:293-308.
17. Bakhiet SM, Fahal AH, Musa AM, Mohamed ES, Omer RF, Ahmed ES, et al. A holistic approach to the mycetoma management. PLoS Negl Trop Dis. 2018;12:e0006391.
18. Ramírez-Soto MC, Tirado-Sánchez A, Bonifaz A. Ocular sporotrichosis. J Fungi. (Basel). 2021;7:951.
19. Zhang Y, Wang Y, Cong L, Yang H, Cong X. Eyelid sporotrichosis: unique clinical findings in 72 patients. Australas J Dermatol. 2016;57:44-7.
20. Freitas DF, de Siqueira Hoagland B, do Valle AC, Fraga BB, de Barros MB, de Oliveira Schubach A, et al. Sporotrichosis in HIV-infected patients: report of 21 cases of endemic sporotrichosis in Rio de Janeiro, Brazil. Med Mycol. 2012;50:170-8.
21. Salzer HJ, Burchard G, Cornely OA, Lange C, Rolling T, Schmiedel S, et al. Diagnosis and management of systemic endemic mycoses causing pulmonary disease. Respiration. 2018;96:283-301.

22. Almeida-Paes R, Bailão AM, Pizzini CV, Reis RS, Soares CM, Peralta JM, et al. Cell-free antigens of *Sporothrix brasiliensis*: antigenic diversity and application in an immunoblot assay. Mycoses. 2012;55:467-75.
23. Garcia Ferreira P, de Souza Lima CG, Noronha LL, de Moraes MC, Silva FC, Lifsitch Viçosa A, et al. Development of a method for the quantification of clotrimazole and itraconazole and study of their stability in a new microemulsion for the treatment of sporotrichosis. Molecules. 2019;24:2333.
24. Song Y, Zhong SX, Yao L, Cai Q, Zhou JF, Liu YY, et al. Efficacy and safety of itraconazole pulses vs. continuous regimen in cutaneous sporotrichosis. J Eur Acad Dermatol Venereol. 2011;25:302-5.
25. Viana PG, Figueiredo AB, Gremião ID, de Miranda LH, da Silva Antonio IM, Boechat JS, et al. Successful treatment of canine sporotrichosis with terbinafine: case reports and literature review. Mycopathologia. 2018;183:471-8.
26. Costa RO, Bernardes-Engemann AR, Azulay-Abulafia L, Benvenuto F, Neves Mde L, Lopes-Bezerra LM. Sporotrichosis in pregnancy: case reports of 5 patients in a zoonotic epidemic in Rio de Janeiro, Brazil. An Bras Dermatol. 2011;86:995-8.
27. Kauffman CA, Bustamante B, Chapman SW, Pappas PG, Infectious Diseases Society of America. Clinical practice guidelines for the management of sporotrichosis: 2007 update by the Infectious Diseases Society of America. Clin Infect Dis. 2007;45:1255-65.

Portuguese Journal of Dermatology and Venereology

Permanyer

Check for updates

Port J Dermatol and Venereol.

REVIEW ARTICLE

The differential diagnoses and complications of scabies variants

Os diagnósticos diferenciais e as complicações das variantes da sarna: uma breve revisão

Jacob Al-Dabbagh[1a], Razan Younis[2], and Rasha Sliman[1]*

[1]Faculty of Medicine, Tishreen University, Latakia; [2]Faculty of Medicine, Tartous University, Tartous. Syria
[a]ORCID: 0000-0002-5596-9738

Abstract

Scabies is a common infection that affects people all over the world and has various presentations and impacts depending on the clinical situation. It is caused by the mite *Sarcoptes scabiei* var. hominis, an obligate ectoparasite that resides in the epidermis of the human skin. In this article, we present a review of the differential diagnoses and complications of scabies and scabies variants. We also present a summary of the etiology and the current diagnostic methods of scabies.

Keywords: Scabies. *Sarcoptes scabiei* var. hominis. Infestation. Parasitism. Differential diagnosis. Complications.

Resumo

A sarna é uma infeção comum que afecta pessoas em todo o mundo e tem várias apresentações e impactos, dependendo da situação clínica. É causada pelo ácaro Sarcoptes scabei var. hominis, um ectoparasita obrigatório que reside na epiderme da pele humana. Neste artigo, apresentamos uma revisão dos diagnósticos diferenciais e das complicações da escabiose e das variantes da escabiose. Apresentamos também um resumo da etiologia e dos métodos de diagnóstico actuais da sarna.

Palavras-chave: Sarna. *Sarcoptes scabiei* var. hominis. Infestação. Parasitismo. Diagnóstico diferencial. Complicações.

Introduction

Scabies is a neglected tropical cutaneous disease that affects people of all ages[1]. Children, adolescents, and elderly individuals are the most frequently affected age groups with no gender predilection[2,3]. However, children are more likely than other age groups to have scabies[2]. The pervasiveness of scabies in children is approximated to be 5-10%, with the highest predominance in children under 2 years old[4].

Poor hygiene, poverty, homelessness, overcrowding, lack of access to medical care, immunodeficiency, indiscriminate sexual activity, and demographic forces (including wars and migration) are significant risk factors for scabies infection[2,5,6]. Several family members may be infested at the same time, as scabies mites are transmitted by direct and indirect transmission[1].

The most prevalent regions of scabies infections are the tropical and subtropical areas, such as Latin America, the Pacific islands, South-east Asia, sub-Saharan Africa, and Northern and Central Australia[7-9].

***Correspondence:**
Jacob Al-Dabbagh
E-mail: jacobaldabbagh0@gmail.com

Received: 20-07-2023
Accepted: 19-09-2023
DOI: 10.24875/PJDV.23000062

Available online: 20-12-2023
Port J Dermatol and Venereol. 2023;81(4):259-266
www.portuguesejournalofdermatology.com

Etiology

Animal mites can be found in six genera: *Chorioptes*, *Cnemidocoptes*, *Notoedres*, *Psoroptes*, *Otodectes*, and *Sarcoptes*, with just the last, addressed in this article[6]. *Sarcoptes scabiei* causes scabies in humans, livestock, and wild animals[6].

The scabies mite (*S. scabiei* var. hominis) is an obligate human parasite that belongs to the *Sarcoptidae* family which is a member of the class *Arachnida* in the subclass *Acari* of the order Astigmata[2]. It is white-brown in color and lives in linear burrows that are dug into the stratum corneum and can be seen by the naked eye as a speck, and skilled dermatologists may be able to notice it using dermoscopy[2,3].

The female mite has a size of approximately 0.4 × 0.3 mm while the male is about two-thirds of the female size[10,11]. The adult mite has four pairs of legs contrasted with the larva which has three pairs of legs[10]. At the beginning of the scabies mite life cycle, which takes about 14-21 days, the fertilized female burrows into the stratum corneum at a rate of 0.5-5 mm/day and lay 2-4 eggs each day that hatch after 48-72 h into larvae and create new burrows[2,5,10]. The larvae take approximately 10-14 days to reach adulthood[10,11]. The life range of a female mite is 4-6 weeks, during which it lays about 40-50 eggs[10]. Adult male mites may enter the burrows in search of food and unfertilized female mites for mating and die shortly after mating[2,3].

The average burden in classical scabies is around 10-20 mites, and between 50 and 250 mites can be found in infants and the elderly[3]. However, thousands to millions of mites are carried by crusted scabies patients[3].

The scabies mites are resistant to soap and alcohol and they either reinfest the host at a different location or infect another human host[2]. In normal room conditions (21°C and 40-80% relative humidity), scabies mites can survive outside the human body for 24-36 h, but this period can be increased with lower temperatures and higher humidity[2]; during this time, they remain able to invade[5]. However, as the amount of time spent away from the host increases, the ability to invade a new host decreases[10].

Scabies mites cannot jump or fly and they are less contagious the longer they are separated from their host[2]. The minimum necessary time for skin-to-skin transmission is 5 min[10]. Scabies symptoms typically begin 3-6 weeks after the primary infestation and 1-3 days after a reinfestation due to an immediate or delayed (type IV) hypersensitivity reaction to the mites' products (feces, eggs, and dead parasites)[12].

Variants of clinical scabies

Classic scabies

Classic scabies is typically characterized as an intensive cutaneous rash with generalized pruritus that worsens at night[6,13]. The classic signs include burrows and papules[6].

The burrow is a short, 1-10 mm long, serpiginous gray line found on the hands and feet, especially the interdigital spaces, and wrists[13]. Burrows are rarely visualized to the naked eye, and lesions are often misdiagnosed as excoriated or impetiginized skin[13]. The papule is usually small and erythematous, often excoriated or covered with a tiny blood clot[6].

The erythematous papular rash is generally symmetrical, with a tendency to affect the anterior axillary folds, periumbilical skin, elbows, volar surface of wrists, interdigital spaces, beltline, thighs, buttocks, ankles, areola area in women, penis, and scrotum in men[13]. The scalp, face, and neck areas are usually spared in adults, but infants and immunocompromised patients may be affected[13].

Crusted scabies

Crusted scabies, also known as Norwegian scabies, manifests as hyperkeratotic plaques that contain high numbers of mites[14]. It often occurs in patients who are immunosuppressed, such as those infected with HIV or after solid organ transplantation[14].

Clinically, lesions present as thick, gray, scaly, hyperkeratotic, and crusted plaques that are diffusely distributed and typically cover the hands, elbows, feet, knees, nail beds, trunk, scalp, and in some cases the entire body[13,14]. In addition, crusted scabies has little to no pruritus[6]. It is extremely contagious, and if no precautions are taken, outbreaks can occur among family members and patients in hospital wards[15].

Nodular scabies

Nodular scabies is an uncommon variant of scabies that is characterized by persistent itchy nodules that can persist even after treatment of the primary infestation[16]. These nodules are violaceous, pruritic, and between 2 and 20 mm in size[13,14]. The appearance of nodular scabies is the result of a hypersensitivity response to scabies mites and other products of the infection[16]. Nodular scabies occurs most commonly on the thighs, axillae, glans, and scrotum[13].

Bullous scabies

It is a rare clinical variant that usually presents in the elderly[13]. It manifests as tense vesicles/bullae, which occur most commonly on the arms, legs, and trunk; they may also be generalized[14]. Less frequently, they appear on the genitals, buttocks, inguinal folds, thighs, neck, and feet[14]. Bullous scabies often occurs in patients with pruritic dermatosis who have been previously treated with systemic and/or topical corticosteroids[14].

Nail scabies

Nail scabies is an abnormal clinical presentation[17]. It is often misdiagnosed and can be the initial presentation of scabies[13]. It affects certain populations such as infants, immunocompromised individuals, and the elderly[18].

It may affect multiple fingernails and/or toenails and manifests as nail plate dystrophy, which remains even after successful treatment[13].

Scabies incognito

This variant of infestation appears after application of the topical corticosteroid[13]. The corticosteroid alters the distinctive symptoms and lesions of the scabies infestation[14].

Diagnostic methods of scabies

Under ordinary conditions, the diagnosis of scabies can be easily made on the basis of the clinical distribution, the presence of skin lesions, and the patient's medical history[19]. However, in certain circumstances, such as patients receiving steroid medications for a prolonged time or those with weakened immune systems, scabies may manifest with an atypical clinical pattern[19]. In addition, it can be difficult to diagnose scabies in infants or the elderly because their clinical features may differ from those of normal adults[19]. Therefore, an accurate diagnosis of scabies infection is essential for patient treatment[19].

The diagnostic procedure of scabies can be divided into two phases: the presumptive diagnosis (history and physical examination) and the definitive diagnosis (investigations)[20].

History and examination

Medical history, physical examination, and history of concomitant infections in family members and close contacts play an important role in the diagnosis of scabies[21].

Based on the history of nocturnal itching and the typical distribution of skin lesions, a preliminary diagnosis can be made[21].

Dermoscopy

Dermoscopy is an accurate method of diagnosing scabies when performed by a trained physician[20]. It is a painless procedure that can lead to better patient compliance[19]. Finding small, dark, and triangular structures at one of the ends of the burrows indicates the existence of the mites[20].

However, darker skin phototypes, hairy areas, and complications caused by scratching (such as excoriations, crusts, bleeding, or microscopic dirt particles) make it difficult to identify the scabies mite with dermoscopy[1]. In crusted scabies, dermoscopy shows multiple burrows and a hyperkeratotic appearance[1]. Anyhow, the main limitation of dermoscopy is low specificity because of lower magnification[10]. Other limitations include low sensitivity in mild disease and operator dependence[10].

Videodermoscopy

Videodermoscopy is a quick, non-invasive diagnostic method with 100% specificity and greater sensitivity than skin scraping[1,10]. Since it does not make the patient uncomfortable, it can be used in patients who are non-cooperative[10]. In addition, it takes less time and reduces the chance of cross-infections[10].

Reflectance confocal microscopy (RCM)

Through RCM, the burrows can be seen as linear segments in the middle of the surrounding epidermis that appear as a "honeycomb" pattern[1,10]. In addition, eggs, feces, larvae, and mites can be seen[10]. RCM is non-invasive and can be used to study the biological behavior of the mite, as it also shows the movement and peristalsis of the mite[10].

Lack of availability and high equipment costs are the limitations of RCM[10]. Furthermore, the high time requirement is another limitation[10].

Optical coherence tomography (OCT)

OCT is comparable to ultrasonography but has a higher resolution and allows visualization of the most

important parts of the skin[1,10]. Mites, burrows, and eggs can be observed and examined[10]. With the ability to detect the mite both vertically and horizontally, OCT can quickly and precisely diagnose scabies *in vivo*[1].

Burrow ink test (BIT)

BIT is helpful for detecting the scabies mite's burrows[1]. A positive BIT results when the ink follows the mite burrow and forms a distinctive, dark, zigzagged line that is easily visible to the naked eye[22]. If one does not have access to a microscope, dermoscopy, or skin biopsy equipment, this test can be helpful[22]. However, this method provides only a partial diagnosis and is unable to distinguish between old and new lesions[1].

Adhesive tape test (ATT)

In outbreaks in nursing homes and other large accommodations, the ATT is a quick and effective procedure[23]. This technique is not recommended for people with fragile skin[23].

Microscopic examination

Microscopic examination of the mites, eggs, or feces from scales obtained by skin scraping or from the skin biopsy confirms the diagnosis of scabies[1].

Skin scrapings at the end of burrows can be used to detect mites, eggs, or feces microscopically[23]. Although the microscopic examination is inexpensive, a negative result does not rule out infestation, as conventional infection contains only 10-15 mites[24].

Skin biopsy is considered one of the most accurate methods for diagnosing scabies[1]. However, skin biopsy is used only to confirm atypical presentations and is not considered part of the standard examination for the diagnosis of scabies[1].

In addition to the previous diagnostic methods, other methods such as modern molecular techniques and serology can help in diagnosing scabies, although standardized laboratory tests for the detection of scabies are not currently available[1].

The following diagram summarizes the currently available diagnostic procedures for scabies (Fig. 1)[1].

Differential diagnoses of scabies variants

The differential diagnosis of scabies is broad and includes various skin disorders[2]. Physicians may use objective evidence to confirm the diagnosis of scabies or subjective observations to meet the criteria for a clinical diagnosis or a suspected diagnosis of scabies when a patient presents with classic symptoms such as itching that worsens at night and lesions suggestive of mite infestation, such as burrows located on the flexor areas[25].

When patients present with atypical symptoms of scabies, physicians may not suspect that it is a mite-associated dermatosis[25]. Therefore, it can be difficult to make a definitive diagnosis of scabies surrepticius (non-classical scabies), especially when the clinical history and morphologic features of the lesions suggest another disease or the lesions are infected with a bacterial or viral infection[25].

In patients with chronic or progressive skin problems, the possibility of scabies should be considered and further diagnostic testing should be performed, especially if the skin is itchy and unresponsive to therapeutic measures[25].

Clinicians should consider the differential diagnoses that may mimic classic scabies, including insect bites, infections (such as tinea corporis, body lice, impetigo, folliculitis, and viral exanthems), drug eruption, and inflammatory or immune-mediated dermatologic conditions (such as papular urticaria and pityriasis rosea)[2,5,10,26].

Insect bites such as fleas, mosquitoes, midges, and bedbugs are commonly found on exposed skin as red, itchy, and clustered papules[26,27]. Papular urticaria manifests as pruritic red and edematous grouped papules/papulovesicles representing hypersensitivity to insect bites[27,28]. The lesions generally prefer the extensor sides of the extremities, although the trunk is also often affected[28].

Folliculitis is identified by erythematous papules and pustules that are asymptomatic, pruritic, or mildly painful, and located around the hair shaft[29]. Although any area that has hair can be affected, folliculitis often affects only the face, scalp, thighs, armpits, and groin[29].

Dermatitis such as eczema, contact dermatitis, and atopic dermatitis is considered also as differential diagnoses of classic scabies[26,27]. Atopic dermatitis manifests as dry, scaly, erythematous, and itchy skin plaques, which commonly affect the face, neck, elbows, and knee extensors of infants, later including the flexures[27].

Gianotti-Crosti syndrome (GCS) is sometimes mistaken for scabies because of the high percentage of acral papules[28]. The extensor sides of the limbs, buttocks, and cheeks all have a symmetrical distribution of papules[28]. In contrast to scabies, GCS is almost never as itchy as scabies; mite burrows and

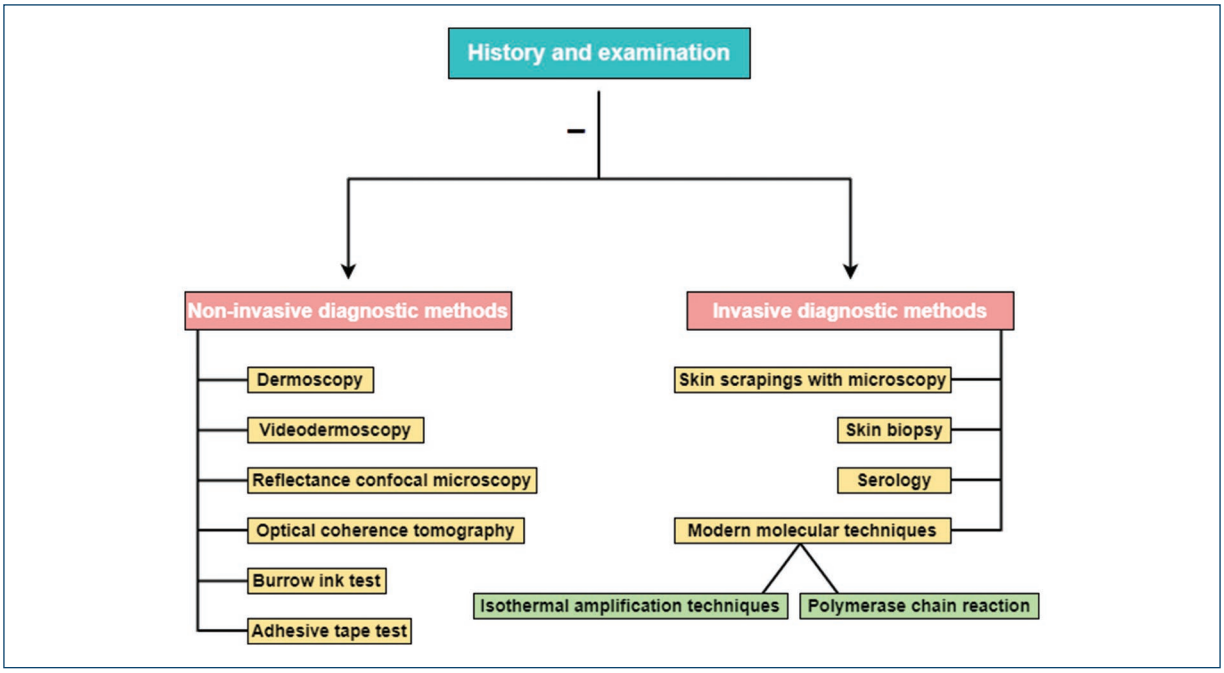

Figure 1. The currently available diagnostic methods for scabies.

excoriations are a regular occurrence in scabies but are the absolute exception in GCS[28].

Other diseases characterized by extensive scaling, such as psoriasis, Darier's disease, drug eruption, lichen planus, palmoplantar keratoderma, and seborrheic dermatitis are potential differential diagnoses for crusted scabies[14,15,26].

Scabies masquerading as an adverse drug reaction has rarely been described[25]. In any patient with a suspected drug eruption who develops pruritic dermatosis after discontinuation of the drug and presents with clinical lesions resembling crusted scabies, the physicians should be aware of the possibility of drug eruption-like scabies (scabies surrepticius)[25].

In a patient with persistent nodular rash, nodular scabies must be investigated as part of the differential diagnosis[16]. Nodular scabies might imitate a solitary cutaneous mastocytoma as it can give a positive Darier sign[2]. Nodular scabies may be mistakenly diagnosed as Langerhans cell histiocytosis, non-Langerhans cell histiocytosis, insect bites, lymphoma, or urticaria pigmentosa[14,30].

In case of blistering is present (bullous scabies), other skin disorders should take into account as differential diagnoses include bullous pemphigoid, bullous impetigo, acquired epidermolysis bullosa, arthropod bite reaction, pemphigus, and dermatitis herpetiformis[2,5].

The lesions in pemphigoid scabies resemble bullous pemphigoid clinically, histologically, and on immunofluorescent findings[13,14]. Subepidermal blisters and eosinophilic dermal inflammation can be seen under a microscope with a potential presence of mites in bullous scabies[14].

The diagnosis of nail scabies is frequently mistaken with onychomycosis, nail psoriasis, traumatic nails, and nail dystrophy[17]. However, nail scabies has been documented in the literature in association with periungual scaling and crusting, distal onycholysis, longitudinal nail splitting, subungual hyperkeratotic deposits, and nail plate deformity/hypertrophy[17].

Infants and young children under 2 years of age are particularly susceptible to scabies[30]. Infants may have diagnostic concerns due to low suspicion of scabies, eczematous changes, and inappropriate therapy, particularly topical steroids[30]. It is important to distinguish infantile scabies from other entities that present similarly in this age group such as infantile acropustulosis, papular urticaria, and atopic dermatitis[10]. Many studies have highlighted the possibility that scabies in infants may resemble other skin diseases, such as bullous pemphigoid, Langerhans cell histiocytosis, adverse drug reactions, lymphomatoid papulosis, lupus erythematosus, psoriasis, or an allergic reaction to an insect bite[30]. In addition, infantile seborrheic dermatitis, which manifests as scaly and greasy plaques on the face and scalp, has a similar appearance to scabies[27].

The differential diagnoses of scabies based on each variant are summarized in the following table (Table 1)[2,5,10,14,15,17,26,31].

Table 1. The differential diagnoses of scabies variant

Scabies variants	Differential diagnoses
Classic scabies	– Atopic dermatitis – Contact dermatitis – Seborrheic dermatitis – Folliculitis – Papular urticaria – Tinea corporis – Impetigo – Body lice – Insect bites – Drug eruption – Varicella – Pityriasis rosea – Infantile acropustulosis – Gianotti-crosti syndrome – Psoriasis – Cutaneous mastocytosis – Langerhans cell histiocytosis
Crusted scabies	– Seborrheic dermatitis – Psoriasis – Palmoplantar keratoderma – Darier's disease – Drug eruption – Lichen planus
Bullous scabies	– Bullous pemphigoid – Bullous impetigo – Acquired epidermolysis bullosa – Arthropod bite reaction – Pemphigus – Dermatitis herpetiformis
Nodular scabies	– Solitary cutaneous mastocytoma – Langerhans cell histiocytosis – Non-langerhans cell histiocytosis – Insect bites – Lymphoma – Urticaria pigmentosa
Nail scabies	– Psoriasis – Onychomycosis – Traumatic nails

Complications of scabies

The secondary medical, psychosocial, and economic factors that are related to the burden of disease must be taken into account when estimating the true global burden of scabies[32]. In the context of the impact of the disease, morbidity associated with scabies is commonly underestimated[22].

Severe rubbing or scratching prompts changes such as bleeding, crusting, or excoriations and can lead to secondary bacterial skin infections[10,14,15].

Secondary infections and impetiginization, most commonly caused by Group A *Streptococcus* (GAS) and *Staphylococcus aureus (S. aureus)*, are the most common complications associated with scabies[10,33]. Staphylococcal and streptococcal growth is promoted by the ability of the scabies mite to disrupt the human complement system by blocking all complement initiation pathways, resulting in decreased neutrophil activity[34]. These bacteria can also be isolated from skin tunnels, and feces indicate that mites may be contributing to the bacteria's distribution[35].

S. aureus can also lead to superficial acute impetiginization, abscesses, ecthyma, cellulitis, paronychia, staphyloderma, erysipelas, and furunculosis[8,34]. However, it can also progress to endocarditis, osteomyelitis, and bacterial sepsis, which can be life-threatening[8]. Whereas, local skin and soft-tissue infections, such as superficial pyoderma, skin abscesses, and cellulitis, as well as more severe necrotizing fasciitis, can be caused by GAS[8].

Impetigo is a common complication of scabies itching, especially in children and patients who live in overcrowded conditions[36]. Impetigo that is caused by *Streptococcus pyogens* can lead to toxin-mediated diseases such as scarlet fever, rheumatic fever, streptococcal toxic shock syndrome, and post-streptococcal glomerulonephritis[10]. *S. pyogens* infection of the skin may also cause reactive arthritis-synovitis, necrotizing fasciitis, and pediatric autoimmune neuropsychiatric disorder[2].

Infectious complications seem to be more severe in crusted scabies[36]. This may be caused by the patient's comorbidities, such as immunosuppression, as well as deeper excoriations that result in invasive infections and severe sepsis, which lead to a high risk of mortality[36,37]. Furthermore, crusted scabies cases may develop generalized lymphadenopathy and eosinophilia[3,20].

Crusted scabies can also cause malodor as a secondary bacterial infections[2]. Colonization of the burrow by *S. aureus* can lead to erythroderma, septicemia, and superinfection with *S. pyogenes*, which causes glomerulonephritis and rheumatic fever[38].

In addition, scabies herpeticum may occur when crusted scabies is superinfected in association with herpes simplex[2].

Systemic complications such as bacteremia, acute post-streptococcal glomerulonephritis, streptococcal and staphylococcal sepsis, acute rheumatic fever, and rheumatic heart disease can be associated with a high risk of mortality[4,33]. Patients with a previous history of scabies are more likely, according to some studies, to develop bullous pemphigoid and chronic kidney disease[39].

Table 2. Scabies complications

Secondary to skin infection		Secondary to itching/ scratching	Psychosocial	Other
Cutaneous	Systemic			
– Superficial acute impetiginization – Superficial pyoderma – Abscesses – Ecthyma – Cellulitis – Paronychia – Furunculosis – Erysipelas – Staphyloderma – Scabies herpeticum – Bullous impetigo – Malodor	– Endocarditis – Osteomyelitis – Bacterial sepsis – Pernicious anemia – Acute post-streptococcal glomerulonephritis – Acute rheumatic fever – Scarlet fever – Rheumatic heart disease – Streptococcal toxic shock syndrome – Chronic kidney disease – Reactive arthritis-synovitis – Necrotizing fasciitis – Pediatric autoimmune neuropsychiatric disorder – Lymphadenopathy – Eosinophilia	– Bleeding – Crusting – Excoriations – Sleep disturbances – Tiredness – Reduced productivity – Reduced ability to concentrate – Increased risk and severity of skin conditions (such as psoriasis and atopic dermatitis)	– Low work attendance – Social stigmatization – Feelings of shame – Loss of performance at school – School absenteeism – Fatigue – Lack of concentration or memory in infants – Intellectual disability – Bipolar disorder	– Significant financial burden – Generalized urticaria

Renal damage without symptoms can occur in scabies patients[40]. The morbidity and mortality associated with chronic renal disease are important late complications of scabies[32].

Scabies patients suffer from a deteriorated quality of life that is linked directly to their itchiness[34]. Up to 90% of scabies patients have sleep disturbances caused by itching[36]. Sleep disturbances may be associated with tiredness, reduced productivity, and reduced ability to concentrate[2]. After eradicating the scabies mite, post-scabetic pruritus can be stubborn and debilitating, and it may last for a long period[2].

Scabies can cause psychosocial complications such as low work attendance, social stigmatization, and feelings of shame[36]. In addition, it can cause loss of performance at school, school absenteeism, fatigue, and lack of concentration or memory in infants[36].

Scabies can cause a significant financial burden, particularly on patients with severe systemic complications[2]. Rarely, scabies patients may develop generalized urticaria[2].

In rare cases, scabies can have unusual complications such as cutaneous vasculitis, vascular purpura, and glomerulonephritis, which may occasionally foreshadow the original disease[41].

Scabies patients also have a higher risk of pernicious anemia, intellectual disability, and bipolar disorder, according to some studies[2].

The complications of scabies are demonstrated in the following table (Table 2)[2-4,8,10,33,34,36,37,39,42].

Conclusion

The physicians must take into account the differential diagnoses of scabies variants to make the proper diagnosis. The physician must also be aware of the complications of scabies and perform an appropriate treatment to achieve a complete recovery from scabies and its complications.

Authors' contributions:

Jacob Al-Dabbagh: wrote the original draft, performed the literature review, and was the supervisor. Razan Younis and Rasha Sliman: performed the literature review and edited the manuscript.

Funding

None.

Conflicts of interest

None.

Ethical disclosures

Protection of human and animal subjects. The authors declare that no experiments were performed on humans or animals for this study.

Confidentiality of data. The authors declare that no patient data appear in this article.

Right to privacy and informed consent. The authors declare that no patient data appear in this article.

Use of artificial intelligence for generating text. The authors declare that they have not used any type of generative artificial intelligence for the writing of this manuscript, nor for the creation of images, graphics, tables, or their corresponding captions.

References

1. Al-Dabbagh J, Younis R, Ismail N. The currently available diagnostic tools and treatments of scabies and scabies variants: an updated narrative review. Medicine (Baltimore). 2023;102:e33805.
2. Leung AK, Lam JM, Leong KF. Scabies: a neglected global disease. Curr Pediatr Rev. 2020;16:33-42.
3. Richards RN. Scabies: diagnostic and therapeutic update. J Cutan Med Surg. 2021;25:95-101.
4. Lobo Y, Wheller L. A narrative review of the roles of topical permethrin and oral ivermectin in the management of infantile scabies. Australas J Dermatol. 2021;62:267-77.
5. Chandler DJ, Fuller LC. A review of scabies: an infestation more than skin deep. Dermatology. 2019;235:79-90.
6. Currier RW, Walton SF, Currie BJ. Scabies in animals and humans: history, evolutionary perspectives, and modern clinical management. Ann N Y Acad Sci. 2011;1230:E50-60.
7. Siddig EE, Hay R. Laboratory-based diagnosis of scabies: a review of the current status. Trans R Soc Trop Med Hyg. 2022;116:4-9.
8. Thompson R, Westbury S, Slape D. Paediatrics: how to manage scabies. Drugs Context. 2021;10:2020\-12-3.
9. Micali G, Lacarrubba F, Verzì AE, Chosidow O, Schwartz RA. Scabies: advances in noninvasive diagnosis. PLoS Negl Trop Dis. 2016;10:e0004691.
10. Arora P, Rudnicka L, Sar-Pomian M, Wollina U, Jafferany M, Lotti T, et al. Scabies: a comprehensive review and current perspectives. Dermatol Ther. 2020;33:e13746.
11. Fischer K, Holt D, Currie B, Kemp D. Scabies: important clinical consequences explained by new molecular studies. Adv Parasitol. 2012;79:339-73.
12. Salavastru CM, Chosidow O, Boffa MJ, Janier M, Tiplica GS. European guideline for the management of scabies. J Eur Acad Dermatol Venereol. 2017;31:1248-53.
13. Hicks MI, Elston DM. Scabies. Dermatol Ther. 2009;22:279-92.
14. Cohen PR. Scabies masquerading as bullous pemphigoid: scabies surrepticius. Clin Cosmet Investig Dermatol. 2017;10:317-24.
15. Goyal NN, Wong GA. Psoriasis or crusted scabies. Clin Exp Dermatol. 2008;33:211-2.
16. Yanes DA, Faith EF. Nodular scabies: a persistent nodular eruption. Dermatol Online J. 2018;24.
17. Tempark T, Lekwuttikarn R, Chatproedprai S, Wananukul S. Nail scabies: an unusual presentation often overlooked and mistreated. J Trop Pediatr. 2017;63:155-9.
18. Abdullah L, Abbas O. Common nail changes and disorders in older people: diagnosis and management. Can Fam Physician. 2011;57:173-81.
19. Park JH, Kim CW, Kim SS. The diagnostic accuracy of dermoscopy for scabies. Ann Dermatol. 2012;24:194-9.
20. Alsyali Z, Alaithan A, Almubarak K, Alibrahim H, Almansour A, Albalawi T, et al. A comprehensive review study on scabies and its associated impact on psycho-social health of an individual. Int J Contemp Res Rev. 2019;10:20700-8.
21. Shimose L, Munoz-Price LS. Diagnosis, prevention, and treatment of scabies. Curr Infect Dis Rep. 2013;15:426-31.
22. Golant AK, Levitt JO. Scabies: a review of diagnosis and management based on mite biology. Pediatr Rev. 2012;33:e1-12.
23. Sunderkötter C, Feldmeier H, Fölster-Holst R, Geisel B, Klinke-Rehbein S, Nast A, et al. S1 guidelines on the diagnosis and treatment of scabies - short version. J Dtsch Dermatol Ges. 2016;14:1155-67.
24. Agyei M, Ofori A, Tannor EK, Annan JJ, Norman BR. A forgotten parasitic infestation in an immunocompromised patient-a case report of crusted scabies. Pan Afr Med J. 2020;36:238.
25. Cohen PR. Drug eruption-like scabies surrepticius: an uncommonly described variant of scabies appearing in a non-classic clinical presentation. Dermatol Online J. 2022;28.
26. Hardy M, Engelman D, Steer A. Scabies: a clinical update. Aust Fam Physician. 2017;46:264-8.
27. Chan OB, O'Brien T, Yazdabadi A, Su JC. The diagnostic challenge of infantile scabies. Hong Kong J Dermatol Venereol. 2020;28:63-6.
28. Brandt O, Abeck D, Gianotti R, Burgdorf W. Gianotti-crosti syndrome. J Am Acad Dermatol. 2006;54:136-45.
29. Durdu M, Errichetti E, Eskiocak AH, Ilkit M. High accuracy of recognition of common forms of folliculitis by dermoscopy: an observational study. J Am Acad Dermatol. 2019;81:463-71.
30. Cölgeçen-Özel E, Ertaş R, Utaş S, Kontaş O. Scabies mimicking mastocytosis in two infants. Turk J Pediatr. 2013;55:533-5.
31. Hill TA, Cohen B. Scabies in babies. Pediatr Dermatol. 2017;34:690-4.
32. Cox V, Fuller LC, Engelman D, Steer A, Hay RJ. Estimating the global burden of scabies: what else do we need? Br J Dermatol. 2021;184:237-42.
33. Kim HS, Hashimoto T, Fischer K, Bernigaud C, Chosidow O, Yosipovitch G. Scabies itch: an update on neuroimmune interactions and novel targets. J Eur Acad Dermatol Venereol. 2021;35:1765-76.
34. Ständer S, Ständer S. Itch in scabies-what do we know? Front Med (Lausanne). 2021;8:628392.
35. Putra IB, Jusuf NK. Scabies with secondary infection resembling kerion-type tinea capitis. Int J Gen Med. 2021;14:163-7.
36. Jannic A, Bernigaud C, Brenaut E, Chosidow O. Scabies itch. Dermatol Clin. 2018;36:301-8.
37. Thomas C, Coates SJ, Engelman D, Chosidow O, Chang AY. Ectoparasites: scabies. J Am Acad Dermatol. 2020;82:533-48.
38. Niode NJ, Adji A, Gazpers S, Kandou RT, Pandaleke H, Trisnowati DM, et al. Crusted scabies, a neglected tropical disease: case series and literature review. Infect Dis Rep. 2022;14:479-91.
39. Khalil S, Abbas O, Kibbi AG, Kurban M. Scabies in the age of increasing drug resistance. PLoS Negl Trop Dis. 2017;11:e0005920.
40. Hay RJ, Steer AC, Engelman D, Walton S. Scabies in the developing world--its prevalence, complications, and management. Clin Microbiol Infect. 2012;18:313-23.
41. Gunarić A, Jurišić K, Šimić D, Penavić JZ, Jozić S, Goluža I. Scabies mimicing child abuse - a case report. Psychiatr Danub. 2017;29 Suppl 2:145-7.
42. Inam W, Walton S, Khan S, Mahmood W. Molecular drug targets for scabies: a medicinal chemistry perspective. Future Med Chem. 2020;12:2225-38.

Portuguese Journal of Dermatology and Venereology

Permanyer

Check for updates

Port J Dermatol and Venereol.

CASE REPORT

A rare T-cell lymphoma in an ankylosing spondylitis patient under immunosuppression with tumor necrosis factor inhibitor

Linfoma de células T num doente com espondilite anquilosante sob imunossupressão com inibidores de necrose tumoral

Despoina Argyropoulou[1a], Ana C. Freitas[2], Mariana Cravo[3b], Joaninha C. Rosa[4c], and José Cabeçadas[4d]*

[1]Department of Pathology, Hospital Garcia de Orta, Almada; [2]Department of Haematology, Instituto Português de Oncologia de Lisboa Francisco Gentil, Lisbon; [3]Department of Dermatology, Instituto Português de Oncologia de Lisboa Francisco Gentil, Lisbon; [4]Department of Pathology, Instituto Português de Oncologia de Lisboa Francisco Gentil, Lisbon. Portugal

ORCID: [a]0000-0002-1068-0359; [b]0000-0002-4584-8289; [c]0000-0002-3162-1876; [d]0000-0001-6232-1596

Abstract

Lymphoproliferative disorders arising in a background of immune deficiency/dysregulation correspond to a spectrum of disorders ranging from non-noxious hyperplasias to aggressive lymphomas, mainly of B-cell type. We describe a case of an Epstein-Barr virus-positive T-cell lymphoma, with a cutaneous presentation and unusual pathological features in a patient under immunosuppression with infliximab. A 60-year-old patient, with a history of ankylosing spondylitis and autoimmune hemolytic anemia, treated with infliximab and low-dose prednisone since 2013, presented with a 7 cm ulcerated, well-demarcated tumor on his left lower back and a 20 cm scaly, well-demarcated erythematous patch in the left scapular region. A skin biopsy revealed a diffuse infiltration of the superficial and deep dermis by atypical, intermediate-size lymphocytes that expressed CD2, CD3, CD56, TIA-1, Granzyme B, TCRδ, and EBER. There was no evidence of epidermotropism, vasculotropism, or necrosis. The fluor-d-glucose positron emission tomography showed a large splenic, hepatic, bone marrow, and nodal uptake. A diagnosis of an extranodal NK/T-cell lymphoma in association with immunosuppression was rendered. With this article, we aim to add awareness to the difficulty of diagnosis, the careful use of immunomodulators, clinical suspiciousness, and surveillance of possible consequences warranted in all patients under prolonged immunosuppression.

Keywords: γδ T lymphocytes. γδ T-cell lymphoma. Extranodal NK/T-cell lymphoma. Epstein-Barr virus. TNF- α inhibitors.

Resumo

No espetro de patologias linfoproliferativas associadas a imunodesregulação/deficiência constam hiperplasias linfoproliferativas e linfomas agressivos, estes últimos predominantemente de células B. Descrevemos um caso de linfoma de células T, Epstein-Barr virus positivo, com apresentação cutânea e características histopatológicas ambíguas, num doente sob imunossupressão com infliximab. Paciente de 60 anos, com antecedentes pessoais de espondilite anquilosante e anemia hemolítica autoimune, tratado com infliximab e baixa dose de prednisolona, desde 2013. Apresentou nódulo cutâneo ulcerado, bem delimitado, com 7 cm na região lombar esquerda e placas eritematosas, bem delineadas, com 20 cm, na região escapular esquerda. A biópsia cutânea revelou uma infiltração difusa da derme superficial e profunda por linfócitos atípicos, de tamanho intermédio, que expressavam CD2, CD3, CD56, TIA-1, Granzima B, TCRδ e EBER. Não se observou epidermotropismo, vasculotropismo ou necrose.

***Correspondence:**
Despoina Argyropoulou
E-mail: despina.argyropoulou@hgo.min-saude.pt

Received: 12-03-2023
Accepted: 28-07-2023
DOI: 10.24875/PJDV.23000022

Available online: 19-09-2023
Port J Dermatol and Venereol. 2023;81(4):267-272
www.portuguesejournalofdermatology.com

A FDG-PET/CT demonstrou hipercaptação esplénica, hepática, medular e nodal. Concluiu-se o diagnóstico de linfoma de células T/NK extranodal em contexto de imunossupressão. Com este artigo pretendemos alertar para a dificuldade diagnóstica, alta suspeição clínica e vigilância atenciosa necessárias em doentes com uso prolongado de imunossupressores.

Palavras chave: Linfócitos de células T γδ. Linfoma de células T γδ. Linfoma de células T/NK extranodal. Vírus Epstein-Barr. Inibidores TNF- α.

Introduction

Lymphoproliferative disorders arising in a background of immune deficiency/dysregulation (primary or acquired) correspond to a spectrum of disorders ranging from non-noxious hyperplasia to aggressive lymphomas[1].

In autoimmune disorders, the risk and type of lymphomas seem to be dependent on the immunomodulatory agent used, the dose, duration, and underlying immunosuppressive disorder[1].

B-cell lymphomas are the most frequent lymphomas associated with immunodeficiency states, whether primary or secondary[1]. Hepatosplenic T-cell lymphoma (HSTCL) is the most frequently reported subtype among the T-cell non-Hodgkin lymphomas associated with exposure to immunosuppressive agents[1].

We present a case of an atypical cutaneous presentation of a systemic extranodal NK/T-cell lymphoma in a patient with ankylosing spondylitis on long-term therapy with tumor necrosis factor-alpha (TNF-α) inhibitor and prednisone.

Case report

A 60-year-old patient, with a history of ankylosing spondylitis and autoimmune hemolytic anemia, under treatment with infliximab and low-dose prednisone for the past 9 years, was referred to the Hematology Department of our Hospital, for a suspected cutaneous lymphoma. On clinical observation, he presented with a 7 cm ulcerated, well-demarcated lesion on his left lower back and in the left scapular region with a 20 cm erythematous, and scaly patch with two infiltrated 4 cm plaques within it (Fig. 1). On palpation, there were no detectable lymphadenopathies or hepato-splenomegaly. The lesions had a 6-month evolution gradually transitioning from patches to plaques and tumours. A skin biopsy of the tumor phase (and later from the plaque phase), performed in the hospital of origin, was reviewed in our pathology department for a histopathological diagnosis. We observed a diffuse infiltration of the superficial and deep dermis by atypical, intermediate-size lymphocytes, with dispersed chromatin (Fig. 2). The neoplastic lymphocytes, evaluated in paraffin-embedded tissue, expressed CD2, CD3, CD56, TIA-1, Granzyme B, and TCRδ and negativity for CD4, CD5, CD7, CD8, CD20, CD30, BCL6, CD278, TCRβ, and PD-1 (Fig. 3). *In situ* hybridization analysis with EBER revealed nuclear positivity in all neoplastic cells. There was no evidence of epidermotropism, vasculotropism, or necrosis.

Due to the ambiguous features of the case a diagnosis of a γδ T-cell lymphoma, Epstein-Barr virus (EBV)-positive was suggested.

We pursued an investigation to determine whether it was a systemic or a primary cutaneous T-cell lymphoma.

A 2-deoxy-2-[18F] fluor-d-glucose positron emission tomography/computed tomography (FDG-PET/CT) and a bone marrow trephine were performed for disease staging. The FDG-PET/CT revealed a stage IV lymphoma with diffuse hypermetabolism of supra- and infra-diaphragmatic lymph nodes, skin, subcutaneous fat, bone marrow, and homogenous hepatosplenomegaly, with the spleen measuring approximately 16 cm.

The bone marrow trephine revealed a diffuse, massive interstitial infiltration of medium-sized T-cell lymphocytes, positive for CD3, CD2, CD45, CD56, and TCR ãä by flow cytometry, compatible with infiltration of the bone marrow by a ãä T-cell lymphoma, and identical to the previously described on the skin (Fig. 4). An identical clonal rearrangement of the T-cell receptor delta gene was detected both in the bone marrow and in the biopsy of the skin lesion.

Plasma EBV DNA levels were 88642UI/mL.

In addition, an identical clonal rearrangement of the T-cell receptor delta gene was detected both in the bone marrow and in the biopsy of the skin lesion.

The authors, based on the histological and immunological features of the skin biopsy and bone marrow involvement, together with the systemic nodal and splenic uptake granted a diagnosis of a systemic γδ T-cell lymphoma, EBV-positive, favoring a diagnosis of an extranodal NK/T-cell lymphoma, with cutaneous involvement and probable association with immunomodulating therapy.

The disease proved to be highly refractory to several therapeutic regimens, including cyclophosphamide, doxorubicin, vincristine, prednisolone, rituximab,

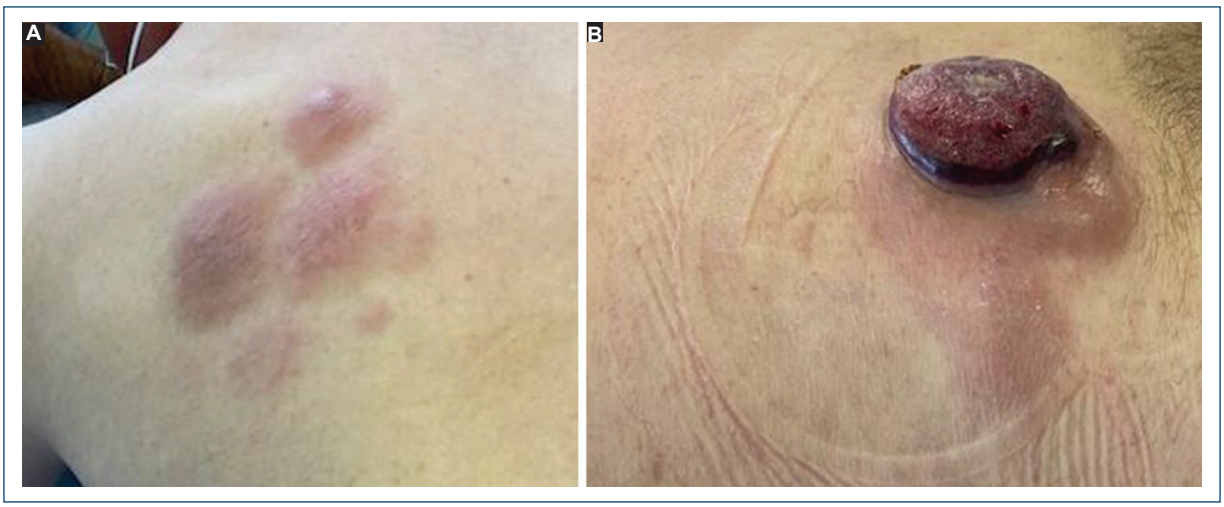

Figure 1. A: patient with a well-demarcated, erythematous, and scaly patch with two infiltrated plaques within it and **B:** an ulcerated and well-demarcated tumor on his left lower back.

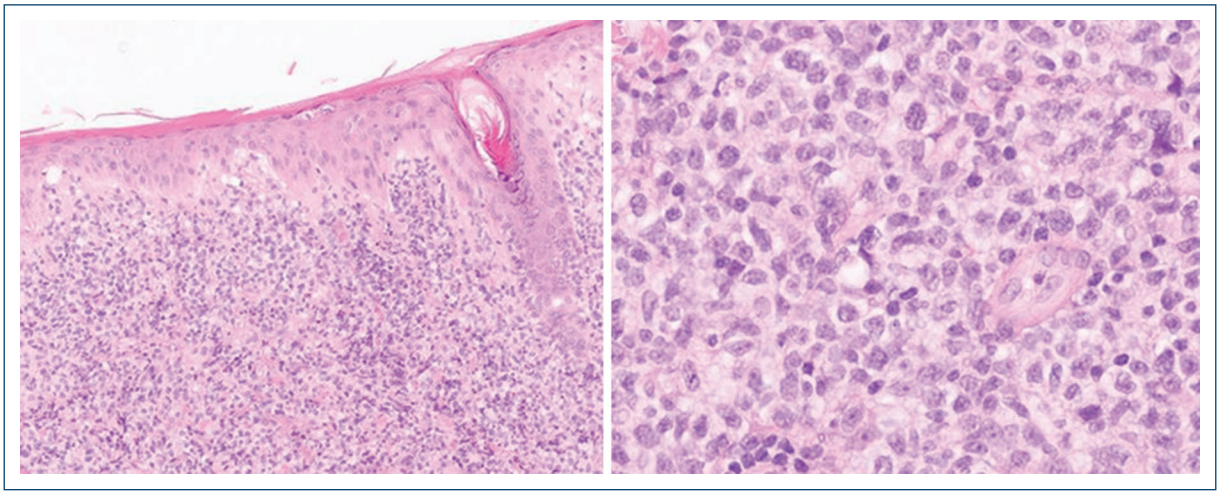

Figure 2. Infiltration of the dermis by atypical, intermediate size lymphocytes, with dispersed chromatin.

ifosfamide, carboplatin, etoposide and rituximab and hyperfractioned-cyclophosphamide, vincristine, doxorubicin, and dexamethasone. In addition to the refractoriness of the disease, several serious infectious complications were documented, as well as hematologic and gastrointestinal toxicity. Following this series of events, the patient died, 2 months after the initial diagnosis (Table 1).

Discussion

γδ T lymphocytes are tissue-restricted cytotoxic lymphocytes accounting for < 5% of the adult T-cell population. They are crucial in immunosurveillance and are mainly lodged in the skin, sinusoids of the liver, red pulp of the spleen, and the intestinal mucosa[2].

Persistent, dose-dependent, treatment with infliximab has been shown to promote the expansion of clonal γδ T-cells *in vivo* and induce proliferation *in vitro*[3]. Furthermore, patients with inflammatory bowel disease or psoriasis seem to have a higher baseline frequency of γδ T-cells when compared to the general population, and, when treated with thiopurines or methotrexate in association with infliximab, demonstrate an even higher baseline frequency and a lower threshold for their expansion[3].

Table 1. Clinicopathologic features of extranodal NK/T-cell lymphoma in a patient with ankylosing spondylitis receiving TNF-α inhibitors

Age/gender	Associated immune disease	Involved organs	Immunomodulator	IHQ-panel	EBV status*	Treatment	Survival+	Status
60 M	Ankylosing spondylitis	Skin, liver, spleen, bone marrow, supra and infra diaphragmatic lymph nodes	Infliximab + prednisone	CD2+, CD3+, CD4-, CD5-, CD7-, CD8-, CD30-, CD56+, TIA-1+, Granzyme-B+, TCR-δ+, TCR-θ-.	+†	CHOP R-ICE HYPER-CVAD	2 mo	Passed away

*EBV status determined by *in situ* hybridization with EBER probe.
†Nuclear positivity in all neoplastic cells. Survival+ represents time, in months (mo), from diagnosis. R-ICE: rituximab, ifosfamide, carboplatin, etoposide.

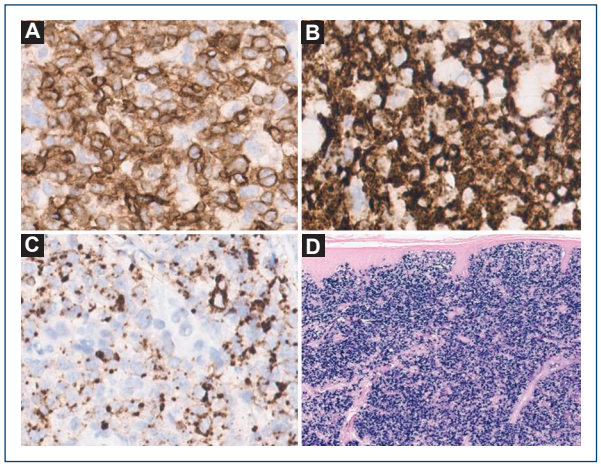

Figure 3. The neoplastic lymphocytes expressed diffuse positivity for **A:** TCR-δ, **B:** TIA-1, and **C:** granzyme B. **D:** *in situ* hybridization analysis with EBER revealed nuclear positivity in all neoplastic cells.

In the literature, so far, seven cases of T-cell lymphomas in association with TNF-α inhibitors have been documented, in patients with ankylosing spondylitis[4-8]. Curiously, the predominant histological subtype is *Mycosis fungoides*/Sezary syndrome. Other types include subcutaneous panniculitis-like TCL, HSTCL, angioimmunoblastic T-cell lymphoma, and one case of anaplastic large-cell lymphoma, also with a cutaneous presentation[4-9].

The description of extranodal NK/T-cell lymphomas, in patients on infliximab therapy, is extremely rare[10-12].

In our case, the cutaneous manifestation of extranodal NK/T-cell lymphoma presented after a 9-year immunosuppression treatment, with infliximab and low-dose prednisone, for ankylosing spondylitis. The systemic presentation, with nodal involvement, also favors this diagnosis over other γδ T-cell lymphomas, such as HSTCL.

This case represents a diagnostic dilemma with clinical, morphological, immunohistochemical, and prognostic overlap to other γδ T-cell lymphomas.

The differential diagnosis includes of a cutaneous γδ cytotoxic T-cell lymphoma is included extranodal NK/T-cell lymphoma (by definition EBV-positive), primary cutaneous γδ T-cell lymphoma (by definition EBV-negative), and cutaneous involvement of an HSTCL (by definition EBV-negative).

In this case, an angiodestructive growth pattern and necrosis, common and desirable features of an extranodal NK/T-cell lymphoma, were not observed[1]. Furthermore, involvement of the bone marrow is rare

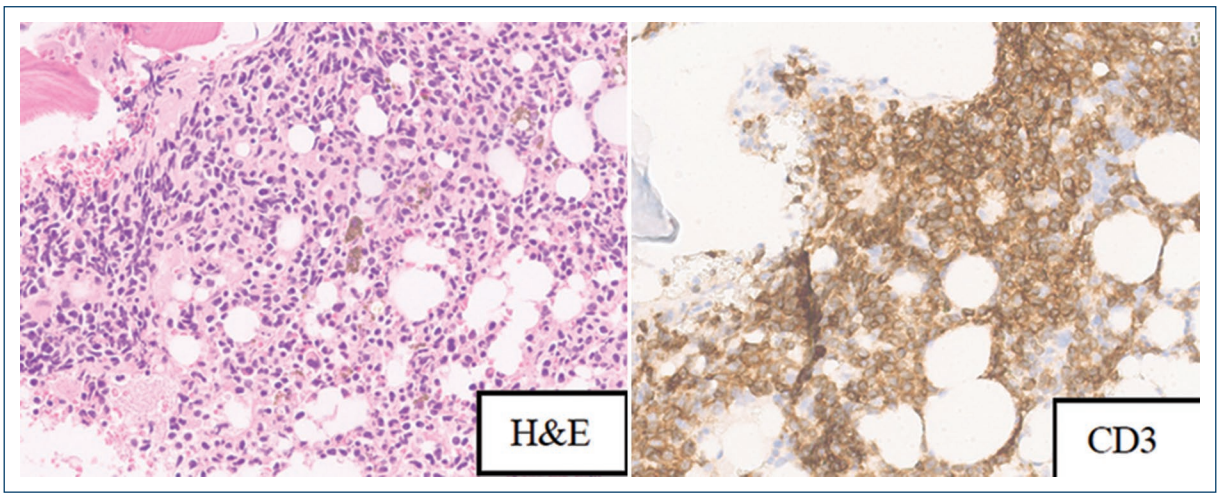

Figure 4. Diffuse interstitial involvement of the bone marrow by CD3-positive neoplastic lymphocytes.

in extranodal NK/T-cell lymphoma. On the other hand, HSTCL is an EBV-negative lymphoma, although rare reports of EBV positivity, as a secondary event of reactivation of the virus, have been reported[1]. HSTCL usually presents with an intrasinusoidal infiltration of the bone marrow and absence of nodal disease[1]. Rare EBV positivity has also been described in primary cutaneous γδ T-cell lymphoma[2], but a systemic disease at diagnosis is extremely rare for a primary cutaneous γδ T-cell lymphoma[13].

For all the above, the histological diagnosis of this case is particularly challenging and emphasizes the importance of a complete clinical history, including past or current medication, and illustrates the difficulty of adequately classify EBV-positive γδ T-cell lymphomas according to the current standardize classification of haematolymphoid tumors. We reinforce the need to further expand and review the classification of these entities.

The cautious use of immunomodulators, including TNF-α inhibitors, high clinical suspicion, and surveillance of possible consequences of prolonged immunosuppression, is warranted to avoid a rapid fatal disclosure associated with the risk of an aggressive lymphoma[14,15].

Conclusion

The histological diagnosis of this case is particularly challenging and emphasizes the importance of a complete clinical history, including past or current medication, and illustrates the difficulty of adequately classify EBV-positive©™ T-cell lymphomas according to the current standardize classification of haematolymphoid tumors. We reinforce the need to further expand and review the classification of these entities.

The cautious use of immunomodulators, including TNF inhibitors, high clinical suspicion, and surveillance of possible consequences of prolonged immunosuppression, is warranted to avoid a rapid fatal disclosure associated with the risk of an aggressive lymphoma[14,15].

Funding

None.

Conflicts of interest

None.

Ethical disclosures

Protection of human and animal subjects. The authors declare that no experiments were performed on humans or animals for this study.

Confidentiality of data. The authors declare that they have followed the protocols of their work center on the publication of patient data.

Right to privacy and informed consent. The authors have obtained approval from the Ethics Committee for analysis and publication of routinely acquired clinical data and informed consent was not required for this retrospective observational study.

Use of artificial intelligence for generating text. The authors declare that they have not used any type

of generative artificial intelligence for the writing of this manuscript nor for the creation of images, graphics, tables, or their corresponding captions.

References

1. Alaggio R, Jong DD, Siebert R, Coupland ES, Naresh NK, Chan J. Lymphoid proliferations and lymphomas associated with immune deficiency and dysregulation. In: WHO Classification of Tumours Editorial Board. Haematolymphoid Tumours. 5th ed., Vol. 11. Lyon, France: International Agency for Research on Cancer; 2022.
2. Caudron A, Bouaziz JD, Battistella M, Sibon D, Lok C, Leclech C, et al. Two atypical cases of cutaneous gamma/delta T-cell lymphomas. Dermatology. 2011;222:297-303.
3. Kelsen J, Dige A, Schwindt H, D'Amore F, Pedersen FS, Agnholt J, et al. Infliximab induces clonal expansion of γδ-T cells in Crohn's disease: a predictor of lymphoma risk? PLoS One. 2011;6:e17890.
4. Deepak P, Sifuentes H, Sherid M, Stobaugh D, Sadozai Y, Ehrenpreis ED. T-cell non-Hodgkin's lymphomas reported to the FDA AERS with tumor necrosis factor-alpha (TNF-α) inhibitors: results of the REFURBISH study. Am J Gastroenterol. 2013;108:99-105.
5. Hruska JC, Bertoli JR, Young DY, Burkhart HP, Googe PB. Primary cutaneous anaplastic large cell lymphoma in a patient receiving adalimumab. JAAD Case Rep. 2015;1:56-9.
6. Kyong HJ, Mie JL, Seong RK, Ko WJ, Hyeon GY, Suk JC, et al. Angioimmunoblastic T cell lymphoma in an ankylosing spondylitis patient treated with etanercept. Mod Rheumatol. 2013;23:817-22.
7. Choi Y, Jeon SY, Yoo WH. Hepatosplenic T-cell lymphoma arising in a patient treated with tumor necrosis factor-α inhibitors for ankylosing spondylitis. J Clin Rheumatol. 2019;25:134-5.
8. Dauendorffer JN, Rivet J, Allard A, Bachelez H. Sézary syndrome in a patient receiving infliximab for ankylosing spondylitis. Br J Dermatol. 2007;156:742-3.
9. Miranda RN, Loo E, Medeiros LJ. Iatrogenic immunodeficiency-associated classical Hodgkin lymphoma clinicopathologic features of 54 cases reported in the literature. Am J Surg Pathol. 2013;37:1895-7.
10. Summers E, Samadashwily G, Florell RS. A unique presentation of an Epstein-Barr virus-associated natural killer/T-cell lymphoproliferative disorder in a white male adolescent. Arch Dermatol. 2011;147:216-20.
11. Chiaki M, Yasushi O, Azusa Y, Chisako I, Masashi A. Epstein-barr virus-associated natural killer/T-cell lymphoma in a patient receiving therapy with anti-tumour necrosis factor and thiopurine. Acta Derm Venereol. 2017;97:273-4.
12. Deneau M, Wallentine J, Guthery S, Gorman OM, Bohnsack J, Fluchel M, et al. Natural killer cell lymphoma in a pediatric patient with inflammatory bowel disease. Pediatrics. 2010;126:e977-81.
13. Lazar JA, Coupland ES, Akkari Y, Berti E, Pulitzer M, Guitart J, et al. Primary cutaneous gamma/delta T-cell lymphoma. In: WHO Classification of Tumours Editorial Board. Haematolymphoid Tumours. 5th ed., Vol. 11. Lyon, France: International Agency for Research on Cancer; 2022.
14. Subramaniam K, Yeung D, Grimpen F, Joseph J, Fay K, Buckland M, et al. Hepatosplenic T-cell lymphoma, immunosuppressive agents and biologicals: what are the risks? Intern Med J. 2014;44:287-90.
15. Pozadzides JV, Pro B. Editorial: hepatosplenic T-cell lymphoma and TNF-α inhibitors. Expert Rev Hematol. 2009;2:611-4.

Portuguese Journal of Dermatology and Venereology

Permanyer

Check for updates

Port J Dermatol and Venereol.

CASE REPORT

Allergic contact dermatitis to enema used to treat inflammatory bowel disease

Dermite de contacto alérgica a enema usado na doença inflamatória intestinal

Maria J. Guimarães[a], Ana G. Lopes, and Teresa Pereira*

Department of Dermatology and Venereology, Hospital de Braga, Braga, Portugal
[a]ORCID: 0000-0002-3247-2470

Abstract

Enemas are commonly used to treat inflammatory bowel disease. It is believed that allergic contact dermatitis (ACD) to enemas is underreported. We describe a case of a 55-year-old woman with non-specific proctitis. The patient was prescribed budesonide rectal enemas. However, 1 day after the first application, erythematous, pruritic plaques emerged in the perineal region and inner thighs. The patient was observed in the emergency department and was ordered to stop the enemas. The patient was referred to dermatology consultation where patch tests were performed using the European/Portuguese baseline series, the corticosteroids series, and the dispersible tablets of budesonide used in the enema. Test readings at 72 h and 7 days revealed positivity for budesonide 0.01% pet, tixocortol pivalate 0.1%, the budesonide tablets used in enemas, perfume mixture 1 (8% pet) and 2 (14% pet) and hydroperoxides of linalool 1%. No lesions have recurred after eviction of the identified allergens. Budesonide is responsible for most ACD to corticosteroids, usually described in association with inhalers or nasal sprays to treat asthma or rhinitis. According to the new classification of corticosteroids by allergenic groups, budesonide, and tixocortol pivalate belong to the same group. Facing a patient with corticosteroid allergy, it is important to determine the individual sensitization/tolerance profile to guide future therapeutic interventions.

Keywords: Allergic contact dermatitis. Enema. Budesonide.

Resumo

Os enemas são frequentemente utilizados no tratamento de doença inflamatória intestinal. Acredita-se que a dermite de contato alérgica (DCA) a enemas seja subnotificada. Descreve-se o caso de uma mulher de 55 anos com proctite inespecífica, a quem foi prescrita a aplicação de enemas retais de budesonido. No entanto, no dia após a primeira aplicação, surgiram placas eritematosas pruriginosas na região perineal e face interna das coxas. A doente foi observada no serviço de urgência e aconselhada a interromper os enemas. A doente foi encaminhada para consulta de Dermatologia onde foram realizados testes epicutâneos com a série básica europeia/portuguesa, a série de corticosteróides e os comprimidos dispersíveis de budesonido utilizados no enema. As leituras às 72 h e 7 dias revelaram positividade para budesonido 0,01%, pivalato de tixocortol 0,1%, comprimidos de budesonido usados nos enemas, mistura de perfume 1 e 2 e hidroperóxidos de linalol 1%. Não houve recidiva das lesões após evicção dos alergénios identificados. O budesonido é responsável pela maioria das DCA aos corticosteróides, maioritariamente descritas em associação com o uso de in inaladores ou sob a forma de spray nasal para tratar asma ou rinite. De acordo com a nova classificação de corticosteróides por grupos alergénicos, o budesonido e

***Correspondence:**
Maria J. Guimarães
E-mail: mjcunhaguimaraes@gmail.com

Received: 02-04-2023
Accepted: 26-07-2023
DOI: 10.24875/PJDV.23000025

Available online: 28-08-2023
Port J Dermatol and Venereol. 2023;81(4):273-275
www.portuguesejournalofdermatology.com

o pivalato de tixocortol pertencem ao mesmo grupo. Perante um paciente com alergia a corticosteróides, é importante determinar o perfil individual de sensibilização/tolerância para orientar futuras intervenções terapêuticas.

Palavras-chave: Dermite de contacto alérgica. Enema. Budesonido.

Introduction

Allergic contact dermatitis (ACD) to enemas is infrequently described in the literature. The greater likelihood of mucosal hypersensitivity, especially in cases of compromised integrity such as inflammatory bowel disease (IBD), makes enemas a potential source of sensitization and allergic reactions[1,2]. Since enemas are commonly used to treat IBD affecting the distal colon and rectum, it is believed that ACD is underreported, as symptoms may be mild and non-specific[1].

Concerning ACD to topical medication affecting the anogenital area, a study from Gilissen et al. showed 9% positivity of patch tests to topical drug preparations, with local anesthetics and corticosteroids being the most frequent sensitizing active principles[3].

Clinical case

A 55-year-old woman, without previous history of atopy, was under gastroenterology (GE) surveillance since 2019 for non-specific proctitis. The patient had been previously medicated with oral mesalazine, ciprofloxacin, and budesonide rectal foam. At the last GE appointment, daily rectal enemas of budesonide were prescribed. However, 1 day after the first application, erythematous, pruritic plaques emerged in the perineal region and inner thighs (Fig. 1). The patient was observed in the emergency department and was ordered to stop the enemas. She was medicated with oral bilastine and topical betamethasone and clotrimazole with the resolution of the skin eruption in 1 week.

To clarify the cause of the skin eruption, the patient was referred to the dermatology department. Patch tests were performed using the European/Portuguese baseline series (Chemotechnique Diagnostics, Vellinge, Sweden), the corticosteroids series (Chemotechnique Diagnostics, Vellinge, Sweden), the dispersible tablets of budesonide and diluent solution (Entocort®) used in the enema and a moisturizing cream used by the patient (Odette®). Test readings at 72 h and 7 days revealed positivity for budesonide 0.1% (+), tixocortol pivalate 0.1% (++), the budesonide dispersible tablets used in enemas (+), perfume mixture 1-8% pet (+) and 2-14% pet (+) and hydroperoxides of linalool 1% (+) (Fig. 2). No lesions have recurred after the eviction of the identified allergens.

Discussion

This case illustrates an ACD to a budesonide-containing enema, with the budesonide foam acting as the likely source of prior sensitization.

Topical corticosteroids (CS) are a relatively common cause of ACD, with a reported positivity in patch testing ranging from 0.5% to 6%[1]. Allergy to CS in nasal sprays and inhalers used to treat asthma or rhinitis is well documented[4]. Surprisingly, there are fewer reports of CS's ACD due to enemas, which possibly relates to the unspecific manifestations of allergic reactions in the anogenital area, sometimes misinterpreted as exacerbations of the previous inflammatory disease[1].

Additional diagnostic obstacles for CS contact allergy include frequent false-negative reactions, as CS tends to suppress a positive patch test reaction and delayed positive reactions, as up to 30% of reactions may be missed if a day 7 reading is not performed[1].

It has been postulated that, similarly to damaged skin, inflammation of the distal bowel may increase rectal CS' penetration and facilitate sensitization[2]. In fact, Malik et al. showed a 9% (four out of 44 patients) prevalence of CS allergy among IBD patients; however, the authors admitted an eventual selection bias which hampers data extrapolation to the entire IBD population[1].

The most used patch test allergens of CS allergy are tixocortol pivalate and budesonide as these are considered markers of steroid allergy[1,2]. By testing both, 90% of corticosteroid-allergic subjects are detected in baseline series[1,2].

According to the new classification of CS by allergenic groups provided by Baeck et al., budesonide and tixocortol pivalate belong to the same group (group 1: the nonmethylated, most often nonhalogenated molecules)[5]. This study further classifies patients allergic to CS into two different subgroups according to the mechanism of immune recognition: patients who react to molecules from one unique group determined by CS molecular charge and patients who may react to the entire spectrum of CS determined by CS molecular structure[5]. Facing a patient with CS allergy, it is important to discern these two subgroups to determine the individual sensitization/tolerance profile[5,6]. In

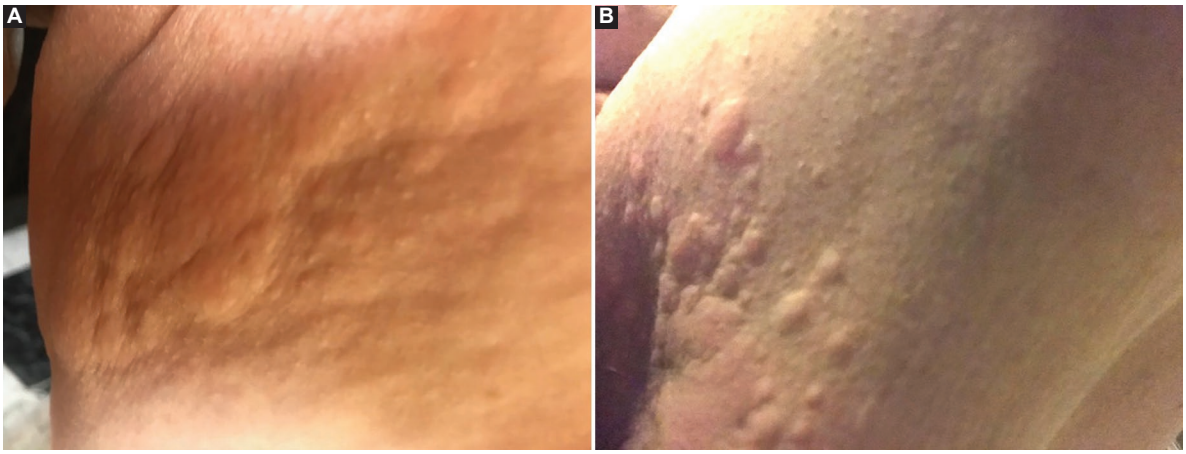

Figure 1. A and **B:** erythematous papules and plaques in inner ties after first budesonide-containing enema.

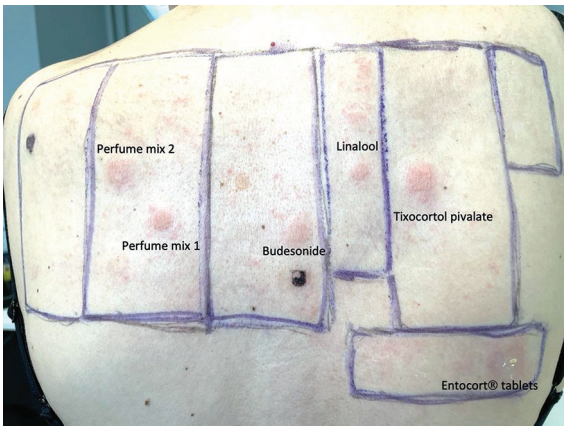

Figure 2. Patch test reading at 72 h: positive reactions for perfume mixture 1 (+) and 2 (+), budesonide 0.01% pet (+), tixocortol pivalate 0.1% pet (++) and Entocort® dispersible tablets pet (+).

this case, one can assume the patient only reacts to molecules from group 1 since the lesions improved under topical betamethasone which belongs to group 3.

ACD to budesonide-containing enema is especially relevant since it is the topical drug that most frequently causes systemic allergic dermatitis[7]. The anorectal mucosa constitutes a relevant route of systemic absorption and its exposure to an allergen can trigger a reaction with variable clinical severity[7].

Funding

None.

Conflicts of interest

None.

Ethical disclosures

Protection of human and animal subjects. The authors declare that no experiments were performed on humans or animals for this study.

Confidentiality of data. The authors declare that they have followed the protocols of their work center on the publication of patient data.

Right to privacy and informed consent. The authors have obtained the written informed consent of the patients or subjects mentioned in the article. The corresponding author is in possession of this document.

Use of artificial intelligence for generating text. The authors declare that they have not used any type of generative artificial intelligence for the writing of this manuscript, nor for the creation of images, graphics, tables, or their corresponding captions.

References

1. Malik M, Tobin AM, Shanahan F, O'Morain C, Kirby B, Bourke J. Steroid allergy in patients with inflammatory bowel disease. Br J Dermatol. 2007;157:967-9.
2. Monk BE, Skipper D. Allergy to topical corticosteroids in inflammatory bowel disease. Gut. 2003;52:297.
3. Gilissen L, Schollaert I, Huygens S, Goossens A. Iatrogenic allergic contact dermatitis in the (peri)anal and genital area. Contact Dermatitis. 2021;84:431-8.
4. Baeck M, Pilette C, Drieghe J, Goossens A. Allergic contact dermatitis to inhalation corticosteroids. Eur J Dermatol. 2010;20:102-8.
5. Baeck M, Chemelle JA, Goossens A, Nicolas JF, Terreux R. Corticosteroid cross-reactivity: clinical and molecular modelling tools. Allergy. 2011;66:1367-74.
6. Hansel K, Marietti R, Bianchi L, Tramontana M, Foti C, Romita P, et al. Cross-reactions to systemic corticosteroids in patients contact sensitized to budesonide. Contact Dermatitis. 2020;83:321-4.
7. De Groot AC. Systemic allergic dermatitis (systemic contact dermatitis) from pharmaceutical drugs: A review. Contact Dermatitis. 2022;86:145-64.

Portuguese Journal of Dermatology and Venereology

Permanyer

Check for updates

Port J Dermatol and Venereol.

CASE REPORT

Alopecia areata and trichotillomania as anxiety repercussions in a child

Alopecia areata e tricotilomania desencadeados pela ansiedade em uma criança

Emilly Neves-Souza[1a], Raissa Marques-Galuppo[2], and Palloma Brandão-Grijó[2]*

[1]Universidade Federal do Espírito Santo (UFES); [2]Faculdade Multivix. Vitória, Brasil
[a]ORCID: 0000-0003-1151-8537

Abstract

Alopecia areata (AA) is a non-scarring alopecia due to an immune-mediated damage to the hair follicles. Trichotillomania (TT) is a psychodermatologic disorder characterized by repetitive hair removal. AA and TT are common causes of hair loss in children and can be triggered by anxiety and distressful events. The simultaneous onset of AA and TT in children is rarely reported in the literature. We describe the case of a 9-year-old male child with a 3-month history of hair loss. The clinical history associated with a detailed trichoscopy led to the diagnosis of concomitant AA and TT.

Keywords: Alopecia areata. Trichotillomania. Hair diseases. Alopecia. Dermoscopy.

Resumo

Alopecia areata (AA) é uma alopecia não cicatricial devida a dano imunomediado dos folículos pilosos. Tricotilomania (TT) é uma desordem psicodermatológica caracterizada pela remoção repetitiva dos fios. AA e TT são causas comuns de alopecia em crianças e podem ser desencadeadas por ansiedade e eventos estressantes. A ocorrência simultânea de AA e TT em crianças raramente é reportada na literatura. Descrevemos o caso de um menino de 9 anos de idade, com história de alopecia de 3 meses de duração. A história clínica associada à tricoscopia detalhada permitiu o diagnóstico de AA e TT simultâneas.

Palabras-clave: Alopecia areata. Tricotilomania. Doenças do cabelo. Alopecia. Dermatoscopia.

Introduction

Alopecia areata (AA) is a non-scarring alopecia marked by immune-mediated damage to the hair follicles. It usually starts in childhood, with a higher prevalence in children than in adults[1,2]. Patients often present a patchy scalp alopecia that may also affect the body[1,2]. Trichotillomania (TT) is a psychodermatologic disorder characterized by repetitive hair removal. The urge to hair pulling is uncontrollable and leads to hair loss, with an increased distress and functional impairment. The age of onset is usually between 10 and 13 years and is more frequent in female patients[3,4].

AA and TT are common causes of hair loss in children and may be triggered by anxiety and distressful events[4,5]. The rapid onset of these diseases can also exacerbate the psychological impairment in susceptible children, as well as psychiatric complications[5].

***Correspondence:**
Emilly Neves-Souza
E-mail: neves.emilly@hotmail.com

Received: 08-05-2023
Accepted: 08-07-2023
DOI: 10.24875/PJDV.23000040

Available online: 28-07-2023
Port J Dermatol and Venereol. 2023;81(4):276-279
www.portuguesejournalofdermatology.com

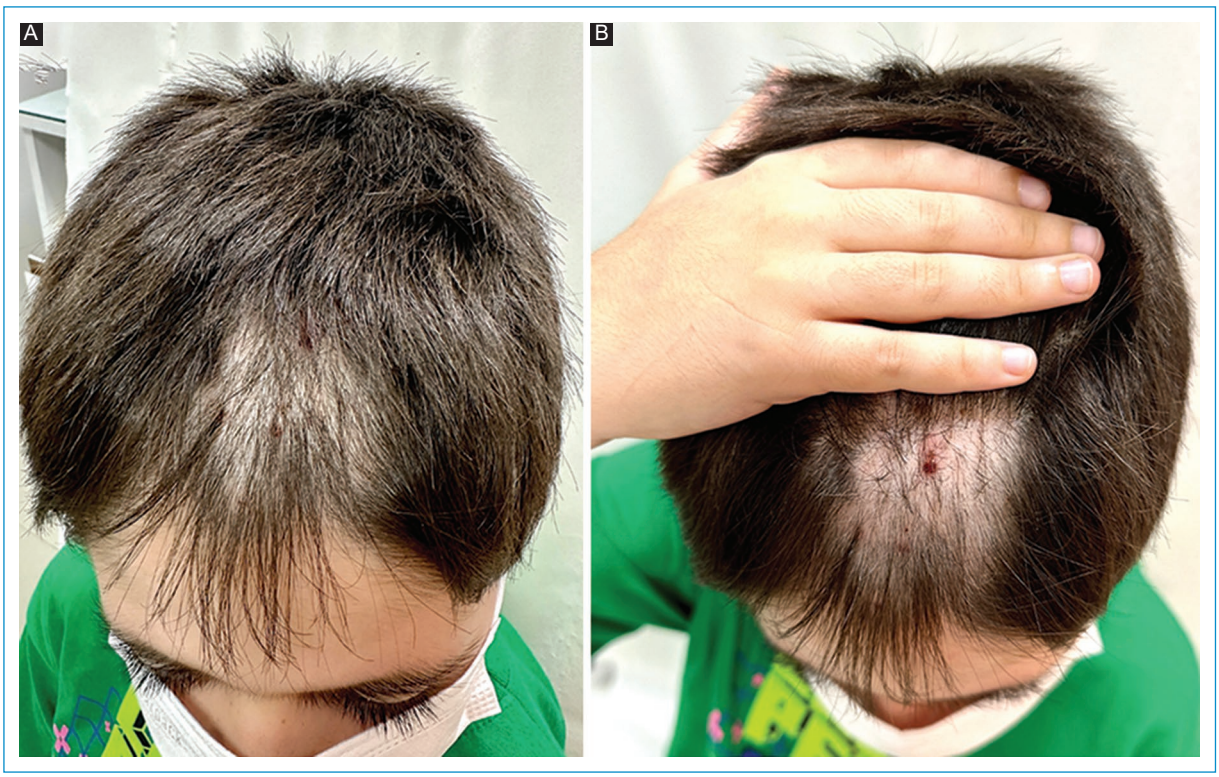

Figure 1. A: static assessment of the scalp hair loss showing an irregular patch of alopecia partially covered by hair shafts. **B:** evaluation after uncovering the alopecic area revealing an irregular patchy alopecia in the frontotemporal region with hemorrhagic crusts.

The simultaneous onset of AA and TT in children is rarely reported in the literature[6]. We describe the case of a 9-year-old male child with a 3-month history of hair loss. The clinical history associated with a detailed trichoscopy led to the diagnosis of concomitant AA and TT.

Clinical case

A healthy 9-year-old boy presented to dermatological consultation with a 3-month history of alopecic area and crusts in the frontal scalp. The mother referred patient's anxiety after his grandfather's death a year ago. He had no relevant medical history. When questioned, he denied hair pulling. The patient identified worsening of the alopecic area over the weeks, with occasional pruritus. His mother noticed progression of the hair loss. Recently, he started therapy sessions with a psychologist to manage his feelings.

Dermatological examination revealed an irregular patch of alopecia in the frontotemporal region with scarce hemorrhagic crusts (Figs. 1A and B). Trichoscopy indicated broken hairs, irregular black dots, exclamation mark hairs, coudability hairs, hairs of different lengths, follicular and interfollicular erythema, short vellus hair, trichoptilosis, hair powder, and hemorrhagic crusts (Figs. 2A-D). The pull test was negative. Eyebrows, nails, and other body areas did not present any alterations. These clinical and trichoscopic findings suggested the association of AA and TT, with signs of scratching. Histopathological study was not performed due to the patient's young age and the risk of anesthetic scar. We prescribed clobetasol propionate emulsion 0.05% daily and topical minoxidil 5%. We also recommended regular psychological appointments. After this therapeutical approach, the lesions showed satisfactory improvement after 3 months.

Discussion

The diagnosis of AA involves medical and family history and a full examination of the scalp, face, and body. Nails should also be analyzed. The hair pull test is recommended, and a positive test indicates an active disease[1]. In the case described, the hair pull test was negative and can be interpreted as a stable alopecia.

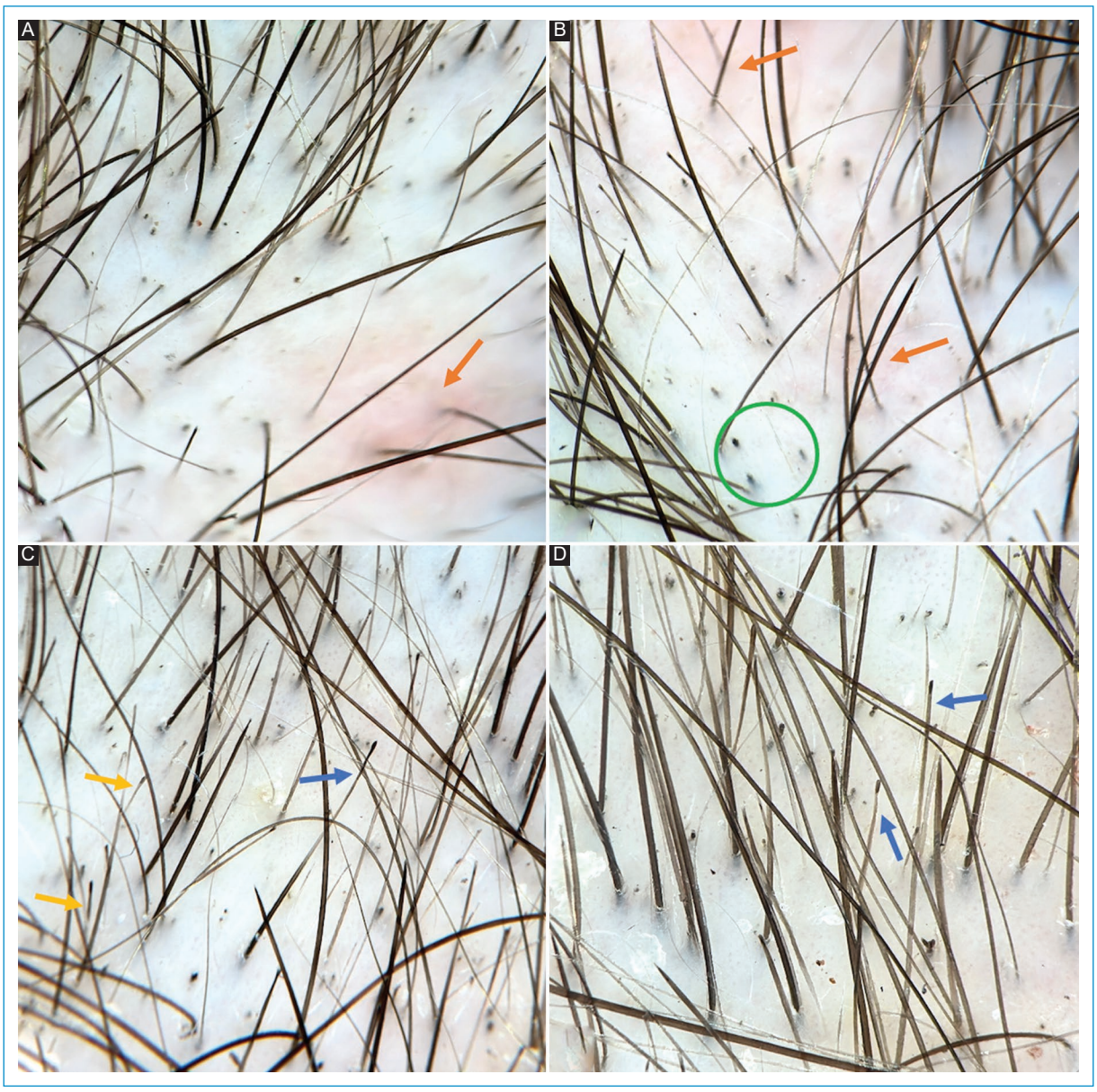

Figure 2. Trichoscopic features of the alopecic area. **A:** broken hairs, perifollicular, and interfollicular erythema (orange arrow), black dots, hair powder, and short vellus hair. **B:** hairs of different lengths, irregular black dots (green circle), perifollicular and interfollicular erythema (orange arrow), trichoptilosis, and short vellus hair. **C:** broken hairs, irregular black dots, exclamation mark hairs (yellow arrow), coudability hairs (blue arrow), hairs of different lengths, hair powder, and short vellus hair. **D:** broken hairs, irregular black dots, coudability hairs (blue arrow), hair powder, and hairs of different lengths.

The most common trichoscopic findings in AA are yellow dots (60-94% of cases), exclamation mark hairs (12-71%), black dots (50%), broken hairs (0-71%), and short vellus hairs (34-100%)[1,7]. These features were identified in the reported patient, as shown in figure 2. Scalp biopsy is rarely necessary and is only needed in inconclusive cases, especially when scarring alopecia cannot be excluded[1].

The diagnosis of TT includes clinical findings, medical and psychiatric history. The physical examination should include trichoscopic analysis[8]. Typical signs are broken hairs of different lengths (80-100% of cases), hair powder (10-88.9%), tulip hairs (10-47.7%), trichoptilosis (34.1-100%), irregular black dots (27.3-100%), flame hairs (25-100%), v-sign (20-70%), hook hairs (11.1-56.8%), and coiled hairs

(4.3-100%)[7,9,10]. Scratching and signs of hemorrhage can be often identified, as in the case reported. Biopsy can be used to confirm the diagnosis in undefined cases[8]. In the patient presented, the clinical history and the trichoscopic findings were sufficient to conclude the diagnosis of AA e TT. There is an important overlap between the trichoscopic features of the two conditions. For instance, black dots and broken hairs are identified in both diseases. We believe we faced both AA and TT because the patchy alopecia presented exclusive findings of AA (exclamation mark hairs and coudability hairs) simultaneously with signs of scratching, hairs of different lengths, and trichoptilosis — typical of TT. This set of alterations could not be explained by an isolated AA or TT, but only by both together.

The first-line treatment for pediatric AA includes topical corticosteroids, as prescribed in this case[1]. Topical clobetasol propionate 0.05% is safe and well-tolerated, with good cosmetic acceptance[1]. Intralesional corticosteroids are also recommended for patchy AA, but the procedure was not the first choice in this case due to the patient's young age and fear of needle. Topical minoxidil is usually indicated as an adjuvant intervention, as used in this case[1]. Other therapy options are topical irritation treatment with diphenylcyclopropenone or anthralin, systemic corticosteroids, phototherapy, methotrexate, hydroxychloroquine, and JAK inhibitors[1,11].

Considering TT, psychotherapy is considered the first-line therapy for pediatric patients[3,12]. Topical anesthetics, corticosteroids, or capsaicin can be helpful to control the urge of scratch[12]. Some studies indicate benefits in the use of n-acetylcysteine, clomipramine, olanzapine, and dronabinol in adults, but there are no specific doses for children[3,12]. The association of AA and TT is rare, but possible and can occur in children. For both diseases, dermatologists and psychologists should work together to manage the anxiety (triggering factor) and reduce the emotional impairment of the hair loss.

Funding

None.

Conflicts of interest

None.

Ethical disclosures

Protection of human and animal subjects. The authors declare that the procedures followed were in accordance with the regulations of the relevant clinical research ethics committee and with those of the Code of Ethics of the World Medical Association (Declaration of Helsinki).

Confidentiality of data. The authors declare that they have followed the protocols of their work center on the publication of patient data.

Right to privacy and informed consent. The authors have obtained the written informed consent of the patients or subjects mentioned in the article. The corresponding author is in possession of this document.

Use of artificial intelligence for generating text. The authors declare that they have not used any type of generative artificial intelligence for the writing of this manuscript, nor for the creation of images, graphics, tables, or their corresponding captions.

References

1. Lintzeri DA, Constantinou A, Hillmann K, Ghoreschi K, Vogt A, Blume-Peytavi U. Alopecia areata-current understanding and management. J Dtsch Dermatol Ges. 2022;20:59-90.
2. Afford R, Leung AKC, Lam JM. Pediatric alopecia areata. Curr Pediatr Rev. 2021;17:45-54.
3. Grant JE. Trichotillomania (hair pulling disorder). Indian J Psychiatry. 2019;61(Suppl 1):S136-9.
4. Henkel ED, Jaquez SD, Diaz LZ. Pediatric trichotillomania: review of management. Pediatr Dermatol. 2019;36:803-7.
5. Simakou T, Butcher JP, Reid S, Henriquez FL. Alopecia areata: a multifactorial autoimmune condition. J Autoimmun. 2019;98:74-85.
6. Brzezinski P, Cywinska E, Chiriac A. Report of a rare case of alopecia areata coexisting with trichotillomania. Int J Trichology. 2016;8:32-4.
7. Gómez-Quispe H, Moreno-Arrones OM, Hermosa-Gelbard Á, Vañó-Galván S, Saceda-Corralo D. Trichoscopy in alopecia areata. Actas Dermosifiliogr. 2023;114:25-32.
8. Torales J, Díaz NR, Ventriglio A, Castaldelli-Maia JM, Barrios I, García O, et al. Hair-pulling disorder (trichotillomania): etiopathogenesis, diagnosis and treatment in a nutshell. Dermatol Ther 2021;34:e13466.
9. Kaczorowska A, Rudnicka L, Stefanato CM, Waskiel-Burnat A, Warszawik-Hendzel O, Olszewska M, et al. Diagnostic accuracy of trichoscopy in trichotillomania: a systematic review. Acta Derm Venereol. 2021;101:adv00565.
10. Martín JM, Montesinos E, Cordero P, Gonzalez V, Ramon D. Trichoscopy features of trichotillomania. Pediatr Dermatol. 2019;36:265-7.
11. Barton VR, Toussi A, Awasthi S, Kiuru M. Treatment of pediatric alopecia areata: a systematic review. J Am Acad Dermatol. 2022;86:1318-34.
12. Hoffman J, Williams T, Rothbart R, Ipser JC, Fineberg N, Chamberlain SR, et al. Pharmacotherapy for trichotillomania. Cochrane Database Syst Rev. 2021;9:CD007662.

Portuguese Journal of Dermatology and Venereology

Permanyer

Check for updates

Port J Dermatol and Venereol.

CASE REPORT

Pityriasis lichenoides et varioliformis acuta-like secondary syphilis: a case report of a rare cutaneous presentation

Relato de um caso de sífilis secundária com apresentação cutânea rara tipo pitiríase liquenóide e varioliforme aguda

Miguel Nogueira[1a], Ema Pos[2], André Coelho[3], Mónica Caetano[1], and Joel Reis[1b]*

[1]Department of Dermatology; [2]Department of Infectious Diseases; [3]Department of Pathology. Centro Hospitalar Universitário de Santo António, Porto, Portugal

ORCID: [a]0000-0001-7420-408X; [b]0000-0002-8007-2420

Abstract

The diagnosis of secondary syphilis can be challenging for clinicians due to its diversified cutaneous presentations. This is particularly true for human immunodeficiency virus (HIV) coinfected patients, who may develop unusual clinical manifestations. We report a case of a 33-year-old male, with HIV-1 infection without treatment, who presented to the emergency department (ED) with a 3-month history of erythematous macules. In the week before presenting to the ED, the lesions had progressed to multiple generalized papulovesicles and papules with central necrosis and serohemorrhagic crust, some exhibiting a "collarette" scale. Nasal discharge, earache, and fever were also present. The clinical picture was compatible with the diagnosis of pityriasis lichenoides et varioliformis acuta (PLEVA). Complementary examinations confirmed the diagnosis of PLEVA-like secondary syphilis, and the patient was successfully treated with benzathine penicillin. Our case highlights the importance of being aware of this rare cutaneous presentation of syphilis.

Keywords: Syphilis. Secondary syphilis. Pityriasis lichenoides et varioliformis acuta. Case report.

Resumo

O diagnóstico de sífilis secundária pode ser particularmente desafiante para os clínicos na sua prática diária dada a sua diversidade de apresentações clínicas, sobretudo nos doentes coinfetados com o VIH, que se caracterizam por manifestações cutâneas particularmente atípicas. Reportamos o caso de um homem com 33 anos de idade, com antecedentes pessoais de infeção por VIH-1 sem tratamento, e que recorreu ao serviço de urgência com quadro com 3 meses de evolução de máculas eritematosas que progrediram na última semana para múltiplas pápulovesículas e pápulas com necrose central e crosta sero-hemorrágica sobreposta, algumas delas com descamação "em colarete", associado a sintomas sistémicos de rinorreia, otalgia e febre. Os achados clínicos eram sugestivos de tratar-se de uma pitiríase liquenóide e varioliforme aguda (PLEVA). O estudo complementar confirmou o diagnóstico de sífilis secundária e o paciente foi tratado com sucesso com toma única de penicilina benzatínica. Este caso reforça a importância do reconhecimento desta forma rara de apresentação cutânea da sífilis secundária.

Palavras-chave: Sífilis. Sífilis secundária. Pitiríase liquenóide e varioliforme aguda. Caso clínico.

***Correspondence:**
Miguel Nogueira
E-mail: miguel.o.nogueira@gmail.com

Received: 04-06-2023
Accepted: 29-07-2023
DOI: 10.24875/PJDV.23000048

Available online: 01-09-2023
Port J Dermatol and Venereol. 2023;81(4):280-284
www.portuguesejournalofdermatology.com

Introduction

Syphilis is an infectious disease caused by *Treponema pallidum* that has long been known for its heterogeneous clinical presentation[1]. If untreated, it can progress through four distinct stages: primary, secondary, latent, and tertiary[1]. Diagnosing secondary syphilis can be particularly challenging in daily practice due to its diversified skin manifestations. It is historically known as "the great imitator" since it can mimic several other conditions such as psoriasis, lichen planus, folliculitis, or pityriasis lichenoides chronica[1]. In addition, unusual clinical manifestations of syphilis are more common in human immunodeficiency virus (HIV)-positive patients[2]. To highlight a particularly rare form of presentation, with few cases well-reported in the literature[3-5], we present a case of pityriasis lichenoides et varioliformis acuta (PLEVA)-like secondary syphilis in a HIV-positive patient.

Clinical case

A 33-year-old male presented to the emergency department (ED) with a 3-month history of a skin rash that started with generalized erythematous macules. In the week before presenting to the ED, the lesions had progressed to multiple generalized papulovesicles and papules with central necrosis and serohemorrhagic crusts, some exhibiting a "collarette" scale, with no pain or pruritus. There was concomitant nasal discharge, earache, and fever, with no mucosal lesions. The patient referred that the lesions had appeared after an occasional job at a poultry farm. He denied high-risk behavior for sexually transmitted infections (STI) but mentioned a bisexual behavior.

Regarding his medical history, the patient had been diagnosed with HIV-1 infection 5 years before but then missed all subsequent appointments and abandoned treatment. A month and a half before the observation in the ED, he had returned for a follow-up of HIV infection. His viral load was 33.900 copies/mL and CD4 lymphocyte count was 632/mm^3 serologic tests for syphilis (venereal disease research laboratory [VDRL] test and chemiluminescence assay [CLIA]) were all negative. He did not return to initiate antiretroviral therapy.

Physical examination demonstrated multiple generalized infiltrated erythematous papules, papulovesicles, and plaques, predominantly on the face and dorsum, with a varioliform-like appearance (Fig. 1A and B). Several lesions had already ulcerated and were covered with a serohemorrhagic crust, resembling a "tache-noir". Some of the rounded lesions presented a "collarette" scale, particularly on his back (Fig. 2A) and feet (Fig. 2B). No mucosal lesions were identified in the oral, genital, or anal regions. There was also generalized lymphadenopathy. The clinical hypothesis of PLEVA, rickettsiosis, disseminated fungal infection, and syphilis was considered.

A skin biopsy revealed interface dermatitis with a predominantly superficial lymphohistiocytic infiltrate, compatible with the suggested diagnosis of PLEVA. Serologies (Rickettsia, hepatitis B, and hepatitis C virus), and tissue culture (for mycobacteria and fungi) excluded other relevant infections. Both treponemal and non-treponemal tests were positive (VDRL 1:256; CLIA positive). Since the previous blood sample (1 month and a half before) was still preserved in the laboratory, the VDRL test was repeated, after dilution, to exclude a prozone effect, and was negative. Immunohistochemical staining using polyclonal antibodies anti-*T. pallidum* (MAD-000624QD from Master *in vitro*, Sevilla, Spain) in skin tissue revealed the presence of multiple spirochetes on the epidermis and dermis, predominantly surrounding the superficial vessels (Fig. 3).

The diagnosis of PLEVA-like early secondary syphilis was assumed, and a single dose of 2.4 million units of intramuscular benzathine penicillin was prescribed. The patient later revealed that he occasionally engaged in transactional sex with men. The remaining workup did not reveal any other STI (Chlamydia Trachomatis, Neisseria Gonorrhoeae, hepatitis B and C viruses). He returned after 3 months, with near-complete resolution of skin lesions and negative VDRL titers. We were lost to follow-up after failing four scheduled appointments.

Discussion

Dermatologists and other clinicians should be aware of the high diversity of syphilis' clinical presentation and this awareness seems to be more important than ever when we look through the current data on the epidemiology of the disease. In spite of not being as common as other STIs, syphilis is a systemic condition with an increasing frequency over the last decade[6,7]. Indeed, a recently published report by the European Center for Disease Prevention and Control revealed that although there has been a deceleration in the escalation of syphilis cases compared to the period of 2010-2017 (with annual rates ≤ 7.0/100,000 population), the incidence of confirmed syphilis cases in 2019 surpassed that of preceding years, reaching a rate of 7.4/100,000 population[8]. The majority of cases in high-income countries occur in men

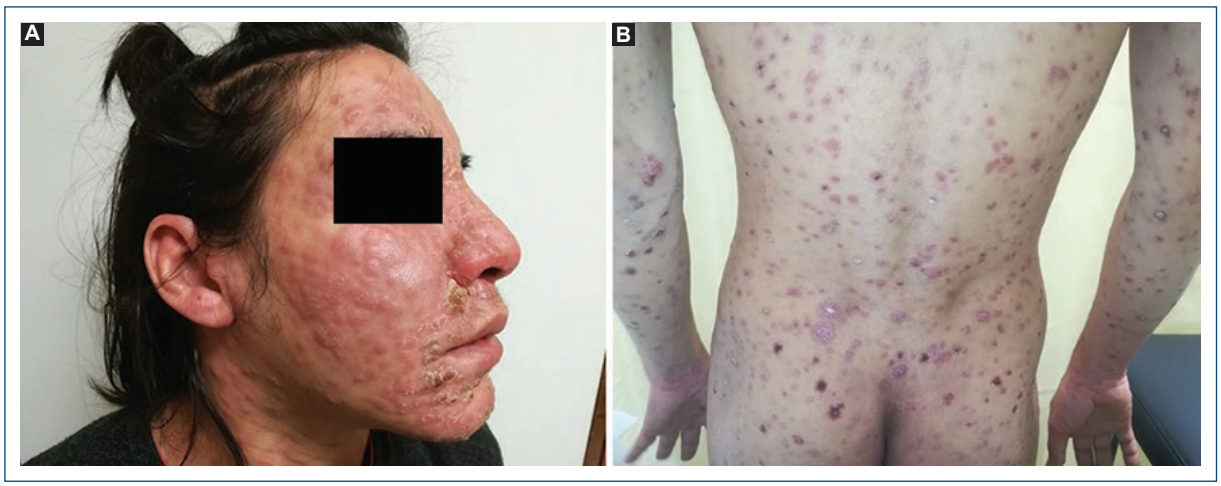

Figure 1. A and **B:** skin presentation on the face and dorsum. Multiple erythematous papules and papulovesicles, some of which have already a necrotic center and are covered by a serohemorrhagic crust.

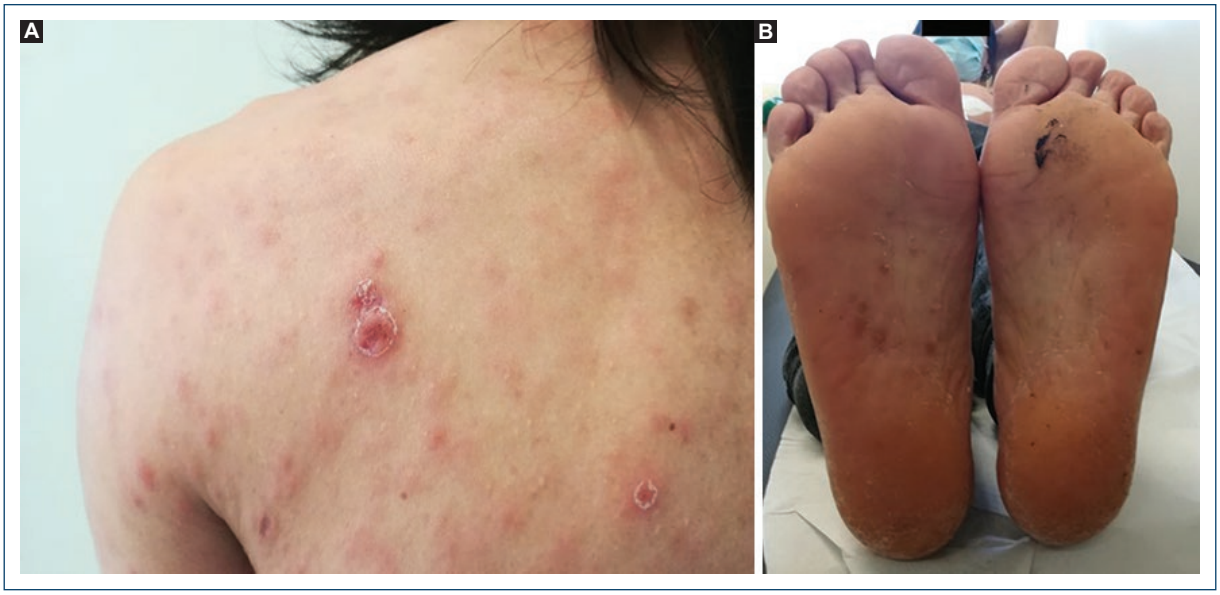

Figure 2. A and **B:** skin presentation on the dorsum and feet. Rounded brown-to-red papules covered by a "collarette" scale.

who have sex with men, with a considering proportion of these patients having a HIV coinfection[2,9]. The diagnosis of syphilis in patients coinfected with HIV poses a clinical challenge due to their heightened susceptibility to develop atypical cutaneous manifestations[2].

PLEVA is a rare cutaneous inflammatory condition more frequent in young adults and children[10]. The pathogenesis of the condition remains poorly understood-several theories have been suggested, including a hypersensitivity reaction that represents an aberrant immune response to bacterial, viral, or protozoal infections[10]. It typically presents as an acute and recurrent skin eruption with a predilection for the trunk, skin flexures, and proximal extremities-and with no mucosal involvement[10]. It is characterized by multiple papules and papulovesicles that rapidly evolve to central necrosis and serohemorrhagic crusts[10]. Occasionally, patients can experience some infectious symptoms, usually before skin lesions. Some patients might develop a Mucha-Habermann disease - de novo or as

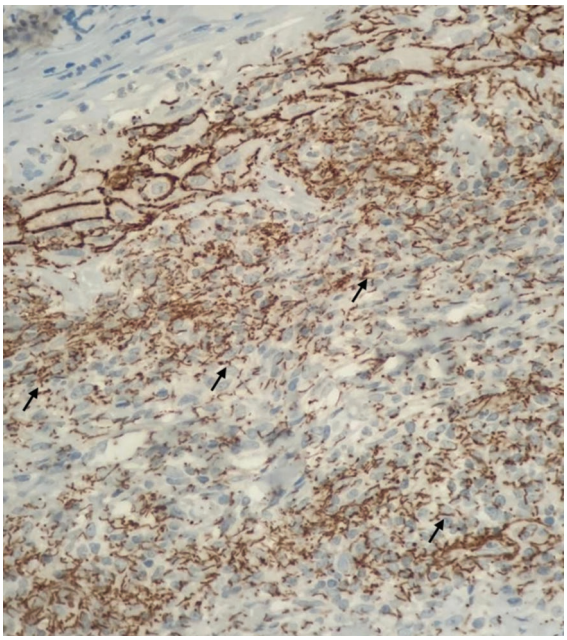

Figure 3. Detection of *Treponema pallidum* using immunohistochemical technique. Multiple spirochetes (black arrow) were detected on the epidermis and dermis using polyclonal antibodies directed against *T. pallidum* in paraffin-embebbed skin biopsy samples. The spirochetes were predominantly deposited around the vessels, particularly the superficial plexus (immunohistochemistry with anti-*T. pallidum* antibody × 200).

a progression from a pre-existing PLEVA -, which seems to be an intensified version of PLEVA, with a more severe clinical presentation and associated symptoms[11].

Regarding our case, the fact that our patient had a past medical history of an uncontrolled HIV infection and of unprotected sexual intercourse led us to think of the possibility of an atypical presentation of secondary syphilis. The ulcerated pustular eruption as a variant of secondary syphilis-higher intensity reported in HIV-coinfected patients-that can mimetize PLEVA describes this case perfectly. The non-occurrence of Jarisch-Herxheimer reaction led us to avoid the historical nomenclature “malignant syphilis” to describe this case of secondary syphilis. In the authors’ opinion, it is plausible that certain cases reported in the literature as PLEVA or Mucha-Habermann in HIV patients could potentially represent the ulcerated pustular eruption of secondary syphilis, which might lead clinicians to be misled by a false-negative VDRL test.

The fact that he mentioned a 3-month evolution of skin lesions, but had negative serologic tests (both VDRL and CLIA) for syphilis 1 month and a half after the beginning of the cutaneous rash is interesting, and should be discussed, but remains to be completely understood. We could have had a prozone phenomenon on VDRL, but a false-negative in a CLIA test occurs in < 1% of the cases[12]. With that being said, we assumed an early secondary syphilis, with two main possibilities that might justify the whole picture: (1) skin lesions had < 3 months of evolution-several reports of simultaneous manifestations of primary and secondary syphilis in HIV patients, which shortens the time to for the appearance of secondary syphilis’ cutaneous manifestations; (2) or there was another cause for the initial multiple erythematous macules that was not detected in the emergency room or on the following outpatient appointment.

All these findings and discussion highlight the need for clinicians to be aware of this differential diagnosis, to be excluded when there is a context that makes it plausible. Furthermore, it reinforces the fact that secondary syphilis might have several cutaneous presentations, particularly in HIV patients, and dermatologists have an extremely important role in reducing the impact of the disease in our community with the right treatment.

Conclusion

In conclusion, heightened awareness of the various clinical forms of syphilis is imperative for clinicians, particularly dermatologists. This awareness is amplified by the escalating prevalence of syphilis despite its relative rarity compared to other STIs - recent epidemiological data, including a report from the European Center for Disease Prevention and Control, underscores the persistent increase in syphilis cases, with a considering proportion of those patients being HIV-coinfected individuals. Ultimately, this clinical case emphasizes the pivotal role of dermatologists in effectively addressing diverse presentations of syphilis within our community.

Funding

None.

Conflicts of interest

None.

Ethical disclosures

Protection of human and animal subjects. The authors declare that no experiments were performed on humans or animals for this study.

Confidentiality of data. The authors declare that they have followed the protocols of their work center on the publication of patient data.

Right to privacy and informed consent. The authors have obtained the written informed consent of the patients or subjects mentioned in the article. The corresponding author is in possession of this document.

Use of artificial intelligence for generating text. The authors declare that they have not used any type of generative artificial intelligence for the writing of this manuscript, nor for the creation of images, graphics, tables, or their corresponding captions.

References

1. Lautenschlager S. Cutaneous manifestations of syphilis : recognition and management. Am J Clin Dermatol. 2006;7:291-304.
2. Karp G, Schlaeffer F, Jotkowitz A, Riesenberg K. Syphilis and HIV co-infection. Eur J Intern Med. 2009;20:9-13.
3. D'Elia Zanella LG, Lellis RF, Khoury Z, Oyafuso LK, Figueiredo-Mello C. Rupioid lesions, PLEVA and superposition phenomenon in malignant syphilis: two case reports in HIV-infected patients. J Eur Acad Dermatol Venereol. 2018;32:e91-2.
4. Pastuszczak M, Wozniak W, Jaworek AK, Wojas-Pelc A. Pityriasis lichenoides-like secondary syphilis and neurosyphilis in a HIV-infected patient. Postepy Dermatol Alergol. 2013;30:127-30.
5. Zhang M, Yu J, Huang H, Zhou C, Zhai Z, You Y, et al. Secondary syphilis in a 12-year-old girl misdiagnosed as pityriasis lichenoides et varioliformis acuta: a case report. Clin Cosmet Investig Dermatol. 2021;14:815-20.
6. Spicknall IH, Kreisel KM, Weinstock HS. Estimates of the prevalence and incidence of syphilis in the United States, 2018. Sex Transm Dis. 2021;48:247-52.
7. Zheng Y, Yu Q, Lin Y, Zhou Y, Lan L, Yang S, et al. Global burden and trends of sexually transmitted infections from 1990 to 2019: an observational trend study. Lancet Infect Dis. 2022;22:541-51.
8. European Centre for Disease Prevention and Control. Syphilis. In: ECDC. Annual Epidemiological Report for 2019. Stockholm: ECDC; 2022. Available from: https://www.ecdc.europa.eu/en/publications-data/syphilis-annual-epidemiological-report-2019
9. Hook EW 3rd, Peeling RW. Syphilis control-a continuing challenge. N Engl J Med 2004;351:122-4.
10. Bowers S, Warshaw EM. Pityriasis lichenoides and its subtypes. J Am Acad Dermatol 2006;55:557-72.
11. Teklehaimanot F, Gade A, Rubenstein R. Pityriasis lichenoides et varioliformis acuta (PLEVA). In: StatPearls. Treasure Island, FL: StatPearls Publishing; 2023. Available from: https://www.ncbi.nlm.nih.gov/books/NBK585135
12. Satyaputra F, Hendry S, Braddick M, Sivabalan P, Norton R. The laboratory diagnosis of syphilis. J Clin Microbiol. 2021;59:e0010021.

Portuguese Journal of Dermatology and Venereology

Permanyer

Check for updates

Port J Dermatol and Venereol.

CASE REPORT

Successful surgical treatment of hypertrophic genital herpes in HIV-infected patient

Tratamento cirúrgico bem-sucedido de herpes genital hipertrófico em paciente infectado pelo HIV

Fernando M. Gonzaga[1a], Adriana B. Campaner[1b], Giulia Marchetti[1c], and Maria A. Longo-Galvão[2d]*

[1]Department of Obstetrics and Gynecology; [2]Department of Pathology. Irmandade de Misericórdia da Santa Casa de São Paulo, SP, Brazil

ORCID: [a]0009-0009-7515-0947; [b]0000-0002-3044-3019; [c]0000-0001-6633-3340; [d]0000-0002-0618-9372

Abstract

Genital herpes is mostly caused by the herpes simplex virus type 2 and is frequent in patients infected with the human immunodeficiency virus. In this setting, the disease may have atypical clinical presentations, including an unusual pseudotumoral hypertrophic form that may cause diagnostic and therapeutic problems, which usually shows an unsatisfactory response to first-line systemic antiretrovirals. The authors report a case of hypertrophic genital herpes refractory to oral acyclovir treatment and effectively treated with surgical excision, with no recurrence after the procedure.

Keywords: Herpes simplex. Herpes genitalis. Vulvar diseases. Human immunodeficiency virus infections. Surgical procedures.

Resumo

O herpes genital é causado principalmente pelo vírus herpes simplex tipo 2, sendo frequente em pacientes infectados pelo vírus da imunodeficiência humana. Nesses casos, a doença pode ter uma apresentação clínica atípica, incluindo a forma hipertrófica, que pode passar despercebida ou ser confundida com outros diagnósticos mais prevalentes. Os antivirais sistémicos de primeira linha apresentam resposta insatisfatória nessa rara forma de apresentação. Os autores relatam um caso de herpes genital hipertrófico refratário ao tratamento com aciclovir e efetivamente tratado com excisão cirúrgica, sem recidiva após o procedimento.

Palavras-chave: Herpes simples. Herpes genital. Doenças vulvares. Infecções por HIV. Procedimentos cirúrgicos operatórios.

Introduction

Herpes simplex virus (HSV) infection is the leading cause of genital ulcers worldwide. HSV type 2 (HSV-2) is the most frequently associated serotype; however, genital lesions can also be caused by HSV type 1 (HSV-1), presenting with a less severe form and with less chance of recurrence[1-4]. The incubation period of the virus can range from 2 to 12 days, with an average of 4 days[1]. Primo-infection is usually asymptomatic, with symptomatic patients showing multiple, widespread, and painful ulcerations on the genitalia[2].

In recurrences, the most common presentation is characterized by 2-3 mm erythematous papules,

***Correspondence:**
Giulia Marchetti
E-mail: dra.giuliamarchetti@gmail.com

Received: 07-06-2023
Accepted: 09-09-2023
DOI: 10.24875/PJDV.23000050

Available online: 05-10-2023
Port J Dermatol and Venereol. 2023;81(4):285-288
www.portuguesejournalofdermatology.com

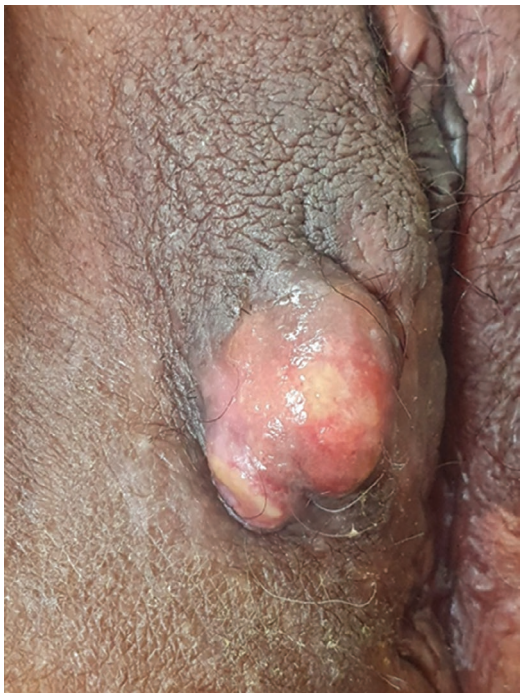

Figure 1. Pseudotumoral hypertrophic genital herpes simplex virus infection in the right labia majora.

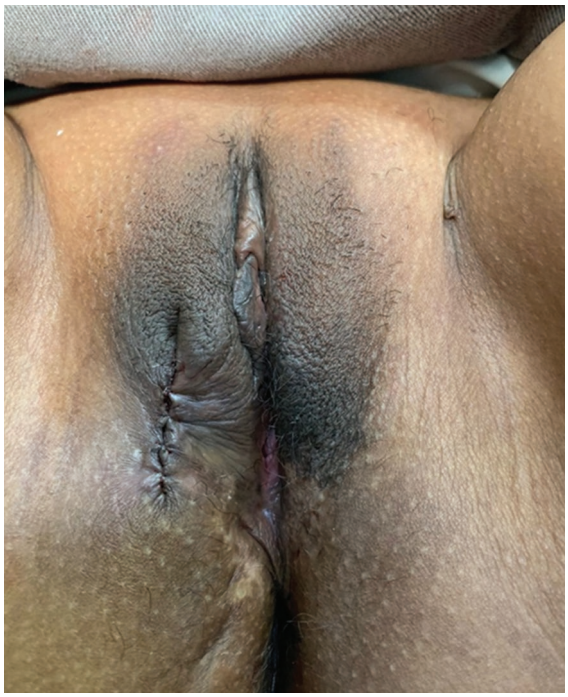

Figure 2. Immediate post-operative image.

followed by formation of clustered vesicles with citrine content that break up and give rise to painful ulcerations[1,4,5]. However, in immunosuppressed patients, HSV infection may present in different forms such as generalized papular eruption, verrucous papules mimicking condyloma, and more rarely as a pseudotumoral hypertrophic form, which can simulate squamous cell carcinoma[5-8].

These atypical presentations of HSV infection require a high degree of clinical suspicion, as well as knowledge of specific therapeutic modalities.

In this context, the authors report a case of hypertrophic genital herpes (HGH) in a patient with concomitant infection by human immunodeficiency virus (HIV), which was unsuccessfully treated with oral antivirals, and resolve after surgical excision.

Case report

A 55-year-old female patient was referred to the Pathology of the lower genital tract Clinic of the Santa Casa de São Paulo Hospital (Brazil), by the primary health care unit. She reported a painful vulvar vegetating mass, with approximately 1 year of evolution and progressive growth. The patient was diagnosed with HIV infection 22 years ago, with good adherence to the antiretroviral therapy, and an undetectable viral load (3 months before). She denied other comorbidities or chronic medication and reported that she was not sexually active for the past 20 years.

A lesional biopsy performed in primary healthcare suggested a herpes virus infection. Thus, the was treated with oral acyclovir at the maximum dose (800 mg 4/4 h) for about 3 months with continuous-lesional growth.

General physical examination was normal and vulvar examination revealed a rounded exophytic mass, with granulomatous appearance, ulcerated areas, and covered with purulent secretion, with approximately 4 cm, in the lateral face of the right labia majora (Fig. 1). In this context, the hypothesis of HGH was considered. Moreover, due to the failure of acyclovir therapy, the patient underwent surgical excision under local anesthesia (Fig. 2). Topical imiquimod was not part of the treatment of the patient reported in this case. The medication was unavailable in the service.

The final histopathological analysis revealed an ulcerated herpetic vulvitis with an intense acute inflammatory reaction and multinucleated cells (Fig. 3). Immunohistochemistry revealed immunoexpression of

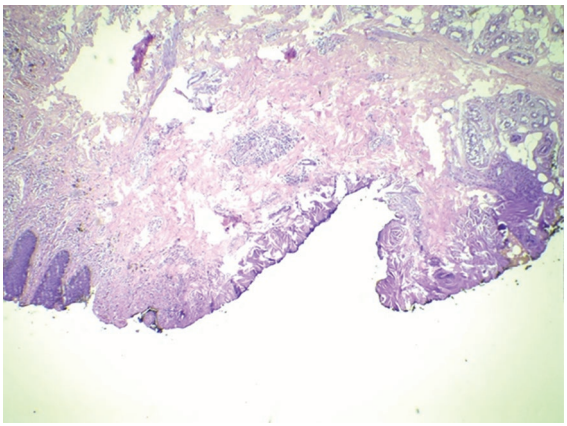

Figure 3. Final histopathological result showing an intense acute inflammatory infiltrate and multinucleated cells in a microscopic magnification of ×4.

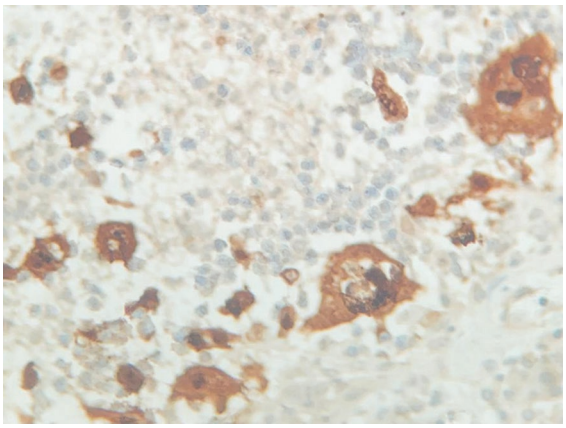

Figure 4. Immunohistochemistry revealing immunoexpression of associated herpes simplex virus type 1 and herpes simplex virus type 2 (research of polyclonal antibodies to herpes simplex virus type 1, type 2, and treponema through the polymer amplification system ENVISION).

associated HSV-1 and HSV-2 (Fig. 4). Therefore, it was decided to maintain oral acyclovir (800 mg 4/4 h) for 30 days. After a follow-up of 12 months, the patient remains stable with no recurrences.

Discussion

HGH is a rare presentation of HSV genital infection that has been described in immunocompromised patients[7], especially in association with HIV infection[6]. The reason why this hypertrophic variant is more prevalent in HIV-positive patients is uncertain, as it appears to have no relation with CD4+ T lymphocyte count, nor with the immunosuppression[5,8]. Possible immunological mechanisms for the development of hypertrophic lesions include increased production of tumor necrosis factor -alpha by factor XIII-positive plamocytoid dendritic cells, promoting a growth of keratinocytes and consequent acanthosis and hyperkeratosis. Furthermore, the decreased production of interferon -gamma, which regulates the activity of keratinocytes, may also contribute to its development[3,5].

This atypical manifestation is characterized by the presence of painful, well-defined exophytic masses with an irregular and ulcerated surface. The lesions are usually located in the perianal region, vulva, penis, and scrotum, but there are reports of similar extragenital lesions[3,7].

The diagnosis depends on a high level of clinical suspicion with clinicopathological correlation, being fundamental for the exclusion of other infectious or non-infectious causes (genital condyloma and squamous cell carcinoma for example)[6,7]. Histopathology and virus identification support the diagnosis, but very small samples may be insufficient for diagnostic confirmation, due to the intense inflammatory response that can mask the diagnosis[5]. Histopathology shows a variable hyperplasia of the epidermis, with multinucleated epithelial cells and dense mixed inflammatory infiltrate composed of lymphocytes, plasma cells, and eosinophils. The identification of HSV in the lesion can be obtained by polymerase chain reaction or immunohistochemical methods[9].

HSV infections in immune compromised patients should be treated with first-line systemic antivirals such as acyclovir (intravenous or oral) valacyclovir and famciclovir (foscanet and cidofovir can be used as a second-line treatment). However, atypical presentations of HSV infections, including HGH, are frequently resistant to antivirals. Thus, surgical excision may be considered, as in the present case[8,10]. A combined therapy of surgical excision with prophylactic antiretroviral drugs may also be an option. Finally, despite the lack of randomized studies, topical imiquimod and oral thalidomide have been described as an effective topical treatment for hypertrophic lesions in immunocompromised patients[8,11,12].

Conclusion

HGH is a rare presentation of HSV genital infection, which must be included in the differential diagnosis of vegetating anogenital lesions in immunocompromised

patients, especially in HIV infection. Biopsy is crucial to exclude other infectious and non-infectious causes. In the therapeutic approach, the likely resistance of this atypical form to antivirals must be considered, and additional topical imiquimod and surgical excision may be effective alternatives.

Funding

None.

Conflicts of interest

None.

Ethical disclosures

Protection of human and animal subjects. The authors declare that no experiments were performed on humans or animals for this study.

Confidentiality of data. The authors declare that they have followed the protocols of their work center on the publication of patient data.

Right to privacy and informed consent. The authors have obtained the written informed consent of the patients or subjects mentioned in the article. The corresponding author is in possession of this document.

Use of artificial intelligence for generating text. The authors declare that they have not used any type of generative artificial intelligence for the writing of this manuscript, nor for the creation of images, graphics, tables, or their corresponding captions.

References

1. Whitley RJ, Roizman B. Herpes simplex virus infections. Lancet. 2001;357:1513-8.
2. Gupta R, Warren T, Wald A. Genital herpes. Lancet. 2007;370:2127-37.
3. Singh S, Tyagi H, Khanduri A, Bansal N, Gupta R. Hypertrophic perianal herpes mimicking squamous cell cancer: a case report and a review of the literature. Cureus. 2022;14:e30649b.
4. Omarova S, Cannon A, Weiss W, Bruccoleri A, Puccio J. Genital herpes simplex virus-an updated review. Adv Pediatr. 2022;69:149-62.
5. Lestre SI, João A, Carvalho C, Serrão VV. Hypertrophic perianal herpes successfully treated with imiquimod. An Bras Dermatol. 2011;86:1185-8.
6. Samaratunga H, Weedon D, Musgrave N, McCallum N. Atypical presentation of herpes simplex (chronic hypertrophic herpes) in a patient with HIV infection. Pathology. 2001;33:532-5.
7. Hanjani NM, Foster DC, Scott GA, Mercurio MG. A genital mass due to herpes simplex virus in a renal transplant recipient. J Low Genit Tract Dis. 2007;11:173-6.
8. Yudin MH, Kaul R. Progressive hypertrophic genital herpes in an HIV-infected woman despite immune recovery on antiretroviral therapy. Infect Dis Obstet Gynecol. 2008;2008:592532.
9. Eyzaguirre E, Haque AK. Application of immunohistochemistry to infections. Arch Pathol Lab Med. 2008;132:424-31.
10. Strehl JD, Mehlhorn G, Koch MC, Harrer EG, Harrer T, Beckmann MW, et al. HIV-associated hypertrophic herpes simplex genitalis with concomitant early invasive squamous cell carcinoma mimicking advanced genital cancer: case report and literature review. Int J Gynecol Pathol. 2012;31:286-93.
11. Bangsgaard N, Skov L. Chronic genital ulceration due to herpes simplex infection treated successfully with imiquimod. Acta Derm Venereol. 2008;88:202-3.
12. Leeyaphan C, Nanchaipruek Y, Phinyo P. Therapeutic outcomes and prognostic factors in patients with hypertrophic herpes simplex infection treated with imiquimod: a systematic review and meta-analysis of individual patient data from case reports and case series. J Dermatol. 2022;49:879-86.

Portuguese Journal of Dermatology and Venereology

Permanyer

Check for updates

Port J Dermatol and Venereol.

CASE REPORT

A rare histologic variant of Kaposi's sarcoma

Uma variante histológica rara de sarcoma de Kaposi

Ana S. Pereira[a], Carolina Figueiredo[b], Rebeca Calado[c], and José C. Cardoso[d]*

Department of Dermatology, Centro Hospitalar e Universitário de Coimbra, Coimbra, Portugal
ORCID: [a]0000-0003-4930-4614; [b]0000-0002-6069-8194; [c]0000-0002-3661-9724; [d]0000-0001-7113-7061

Abstract

An 80-year-old male presented with a 3-year history of progressive violaceous and edematous plaques on both hands. The remaining physical examination was unremarkable and systemic symptoms were absent. All complementary investigations were negative, including serology testing for human immunodeficiency virus. Skin biopsy revealed a dermal vascular proliferation, composed of angulated vessels dissecting collagen bundles, lined by flattened endothelial cells without atypia. Immunohistochemistry showed positive staining for human herpesvirus 8, CD31, and erythroblast transformation-specific-related gene, confirming the diagnosis of lymphangioma-like Kaposi's sarcoma (LLKS). LLKS represents a rare pathological variant of all Kaposi's sarcoma (KS) subtypes, which is noticeable for the lymphangioma-like spaces that are usually only focally found. We present a case of LLKS as a variant of classic KS to raise awareness among dermatologists for this uncommon morphologic expression of KS and its distinctive histologic pattern.

Keywords: Kaposi sarcoma. Lymphangioma. Human herpesvirus-8. Pathology.

Resumo

Um homem de 80 anos apresentou um quadro progressivo com 3 anos de evolução de placas violáceas e edematosas em ambas as mãos. O restante exame físico não revelou alterações e sintomas sistémicos estavam ausentes. Todos os exames complementares foram negativos, incluindo a serologia para VIH. A biopsia cutânea revelou uma proliferação vascular dérmica composta por vasos angulados, revestidos por células endoteliais achatadas sem atipia, que dissecavam os feixes de colagénio. A imunohistoquímica revelou positividade para HHV-8, CD31 e ERG, confirmando o diagnóstico de sarcoma de Kaposi semelhante a linfangioma (SKSL). O SKSL representa uma variante histológica rara de todos os subtipos de sarcoma de Kaposi (SK), que se destaca pelos espaços semelhantes a linfangiomas, normalmente encontrados apenas de forma focal. Apresentamos um caso de SKSL como uma variante do SK clássico para sensibilizar os dermatologistas para esta expressão morfológica incomum de SK e para o seu padrão histológico distinto.

Palavras-chave: Sarcoma de Kaposi. Linfangioma. Herpesvírus humano 8. Patologia.

***Correspondence:**
Ana S. Pereira
E-mail: sfigpereira@gmail.com

Received: 24-06-2023
Accepted: 26-07-2023
DOI: 10.24875/PJDV.23000054

Available online: 29-08-2023
Port J Dermatol and Venereol. 2023;81(4):289-292
www.portuguesejournalofdermatology.com

Introduction

Kaposi's sarcoma (KS) is a low-grade vascular neoplasm caused by human herpesvirus 8 (HHV-8) with a broad spectrum of clinicopathological manifestations[1].

For the past decades, multiple histologic variants of KS have been reported, namely the lymphedematous subtypes, which include lymphangioma-like KS (LLKS), lymphangiectatic KS, and bullous KS[2].

LLKS corresponds to < 5% of all reported KS cases and is mostly defined by the presence of ectatic vascular spaces with a labyrinthine architecture that dissects collagen bundles[3].

We hereby present the case of a patient with lymphangioma-like classic KS, reviewing the clinical and pathological features of this rare entity.

Case report

An 80-year-old male, without relevant past medical history, presented to our department with erythematous to violaceous edematous plaques on the dorsum of both hands, especially on his right side (Fig. 1). These were soft and easily compressible lesions which had been slowly growing for 3 years and were now starting to limit his daily activities. On physical examination, no other mucocutaneous lesions were identified and lymph nodes were not palpable.

The patient denied any systemic symptoms, as well as prior malignancy or radiation therapy.

Routine laboratory workup, including complete blood count, was normal and serology testing for human immunodeficiency virus was negative. Additional investigation included a chest X-ray, an abdominal computed tomography scanning, and a fecal occult blood test, which were all negative.

A skin punch biopsy was performed on the dorsum of the right hand and revealed an ill-defined vascular proliferation on the dermis admixed with an inflammatory infiltrate of lymphocytes and rare plasma cells (Fig. 2A). The proliferation was composed of anastomosing angulated spaces lined by flattened endothelial cells, dissecting collagen bundles and surrounding pre-existing adnexal structures and blood vessels (Fig. 2B). No significant cytological atypia or mitoses was observed. There was no relevant hemosiderin deposition. Immunohistochemistry showed diffuse positive staining for HHV-8 (Fig. 3), as well as positive expression of CD31 and erythroblast transformation-specific-related gene (ERG) by endothelial cells.

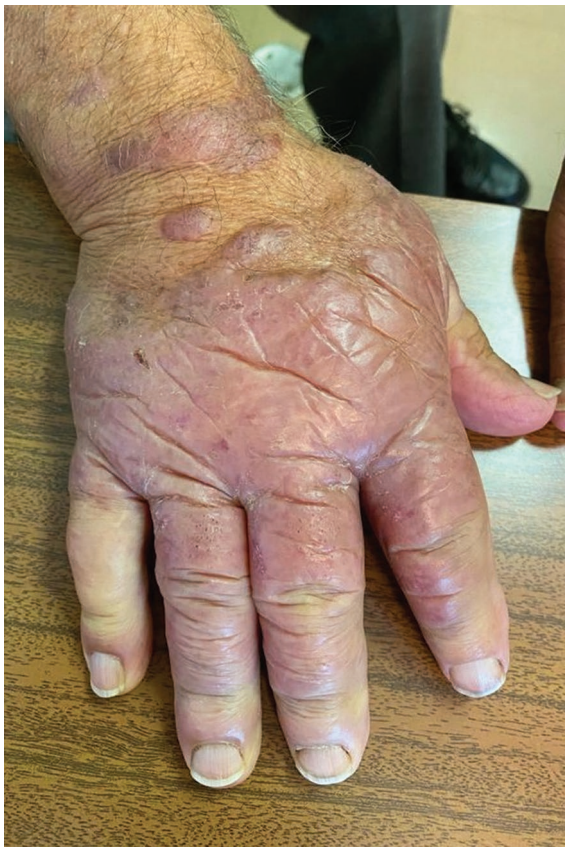

Figure 1. Violaceus and edematous plaques on the dorsum of the right hand and fingers.

A diagnosis of lymphangioma-like Kaposi sarcoma (LLKS) was established. Therapeutic options were discussed but the patient declined any treatment, so a "wait-and-see" approach was adopted. At the last follow-up visit, his lesions remained stable.

Discussion

KS is a multifocal vascular neoplasm with four epidemiological subtypes recognized by the World Health Organization: classic or mediterranean, endemic or African, iatrogenic or post-transplant and epidemic or Acquired immunodeficiency syndrome-associated[4].

Mucocutaneous lesions of KS typically evolve from early macules (patch stage) into plaques (plaque stage) that may later grow into larger nodules (tumor stage)[1]. Extracutaneous locations, most commonly lymph nodes, lungs, or the gastrointestinal tract, may also be affected[1].

Histologic features of KS vary with the stage of the lesion (patch, plaque, or nodule) but generally include ill-defined fascicles of spindle cells associated with

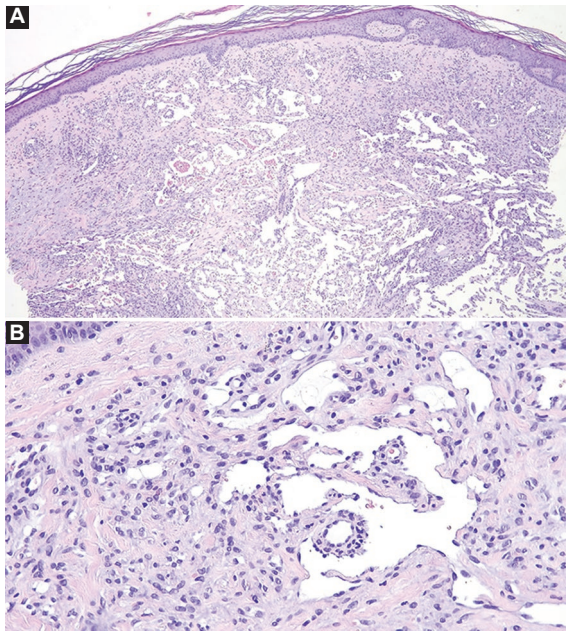

Figure 2. A: vascular proliferation with numerous thin-walled ectatic vessels dissecting collagen bundles and anastomosing lymphangioma-like spaces (hematoxylin and eosin [H&E], ×10); **B:** lymphangioma-like ectatic immature vessels lined by single-layered endothelial cells with isolation of one pre-existing vessel (H&E, ×100).

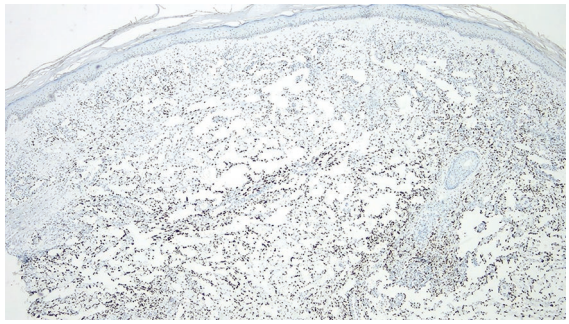

Figure 3. Positive diffuse immunostaining for human herpesvirus 8.

slit-like vascular spaces that dissect the dermis and sometimes circulate around adnexal structures and pre-existing native vessels ("promontory" sign)[5]. A lymphoplasmacytic inflammatory infiltrate, extravasated red blood cells, hemosiderin deposits, and occasional hyaline globules are additional histologic clues[1,5].

Over the years, numerous pathological KS variants have been described such as anaplastic, bullous, telangiectatic, keloidal, verrucous, micronodular, ecchymotic, pyogenic granuloma-like and the lymphedematous subtypes, which comprise lymphangiectatic, lymphangioma-like and bullous KS[1,2].

Lymphangioma-like KS (LLKS) corresponds to < 5% of all reported KS cases and may virtually occur in all epidemiological settings[6], although Ramirez et al. suggest a higher prevalence in patients with classic KS[5].

Previous irradiation and chronic lymphedema have been hypothesized as risk factors for the development of LLKS, but their presence is not mandatory[7,8].

Clinically, LLKS is characterized by the presence of tense vesiculobullous lesions with a serious content[9,10]. However, blisters are not always present and, in some cases, the clinical presentation may be indistinguishable from typical KS lesions[6].

This entity affects mainly the extremities and is more frequent in males, usually above the sixth decade of life[11,12], although a lower mean age at onset (45.1 years) has been reported in 2017[6].

On histology, LLKS stands out for its distinctive anastomosing networks of ectatic vessels in the dermis, which are lined by a layer of flat endothelial cells with no - or very mild - atypia[3,5], resembling the dilated lymphatic channels of a lymphatic tumor, such as a benign lymphangioendothelioma/acquired progressive lymphangioma[2]. By contrast to classic KS, there is no prominent population of spindle cells[13] and red blood cells, lymphocytes or thrombi are usually absent in those spaces[5].

These findings are normally found in up to 50% of the lesional tissue, with adjacent typical KS histologic features that make the diagnosis easier[5]. On the other hand, when lymphangioma-like spaces occupy the entire lesion, differential diagnosis with other vascular tumors such as hemangiomas or hemangioendotheliomas may be challenging[3]. Immunohistochemical studies with positive staining for endothelial cell markers (CD31, CD34, and ERG), lymphatic markers (D2-40) and especially for HHV-8 may be key for confirming the diagnosis[7,14].

The treatment of LLKS is similar to conventional KS, depending on the patient's symptoms, immune status, the number of lesions, and the involvement of extracutaneous sites[6].

Unlike other KS histologic variants[2], LLKS seems to have prognostic significance, with a more indolent course than the traditional classic subtype[6]. This helped to further validate the "wait-and-see" option taken together with the patient in our case.

We believe this case is a good example of lymphangioma-like classic KS, presenting with the typical histologic features but some less common clinical findings as the absence of bullae.

Funding

None.

Conflicts of interest

None.

Ethical disclosures

Protection of human and animal subjects. The authors declare that no experiments were performed on humans or animals for this study.

Confidentiality of data. The authors declare that they have followed the protocols of their work center on the publication of patient data.

Right to privacy and informed consent. The authors have obtained the written informed consent of the patients or subjects mentioned in the article. The corresponding author is in possession of this document.

Use of artificial intelligence for generating text. The authors declare that they have not used any type of generative artificial intelligence for the writing of this manuscript nor for the creation of images, graphics, tables, or their corresponding captions.

References

1. Radu O, Pantanowitz L. Kaposi sarcoma. Arch Pathol Lab Med. 2013;137:289-94.
2. Grayson W, Pantanowitz L. Histological variants of cutaneous Kaposi sarcoma. Diagn Pathol. 2008;3:31.
3. Scott B, Griffin JR. Lymphangioma-like classic Kaposi sarcoma. Int J Dermatol. 2017;56:e141-2.
4. El-Naggar AK, Chan JK, Grandis JR, Takata T, Slootweg PJ. WHO Classifcation of Head and Neck Tumours. 4th ed. Lyon: IARC Press; 2017.
5. Ramirez JA, Laskin WB, Guitart J. Lymphangioma-like Kaposi sarcoma. J Cutan Pathol. 2005;32:286-92.
6. Martínez-Ortíz F, Gómez-Avivar MP. Lymphangioma-like Kaposi sarcoma. Actas Dermosifiliogr. 2017;108:268-71.
7. Davis DA, Scott DM. Lymphangioma-like Kaposi's sarcoma: etiology and literature review. J Am Acad Dermatol. 2000;43:123-7.
8. Anderson LA, Lauria C, Romano N, Brown EE, Whitby D, Graubard BI, et al. Risk factors for classical Kaposi sarcoma in a population-based case-control study in Sicily. Cancer Epidemiol Biomarkers Prev. 2008;17:3435-43.
9. Mohanna S, Sanchez J, Ferrufino JC, Bravo F, Gotuzzo E. Lymphangioma-like Kaposi's sarcoma: report of four cases and review. J Eur Acad Dermatol Venereol. 2006;20:1010-1.
10. Tay YE, Attard NR, Greenblatt D, Morris-Jones R, Stefanato CM. An unusual presentation of toe blisters. Clin Exp Dermatol. 2020;45:786-8.
11. Kandemir NO, Barut F, Gun BD, Tekin NS, Keser SH, Ozdamar SO. Histopathological analysis of vesicular and bullous lesions in Kaposi sarcoma. Diagn Pathol. 2012;7:101.
12. Vázquez-Osorio I, Mallo-García S, García-Alcalde E, González-Sabín M, Gonzalvo-Rodríguez P, Rodríguez-Díaz E. Palmoplantar lymphangioma-like Kaposi sarcoma. J Dtsch Dermatol Ges. 2019;17:192-4.
13. Cossu S, Satta R, Cottoni F, Massarelli G. Lymphangioma-like variant of Kaposi's sarcoma: clinicopathologic study of seven cases with review of the literature. Am J Dermatopathol. 1997;19:16-22.
14. Schmid H, Zietz C. Human herpesvirus 8 and angiosarcoma: analysis of 40 cases and review of the literature. Pathology. 2005;37:284-7.

Portuguese Journal of Dermatology and Venereology

Permanyer

Check for updates

Port J Dermatol and Venereol.

DERMATOLOGY IMAGES

Atypical porphyria cutanea tarda mimicking morphea

Porfiria cutânea tarda atípica mimetizando morfeia

Maria J. Guimarães[a], Carlos M. Nogueira, Catarina Cerqueira, Ana G. Lopes, Celeste Brito, and Catarina Araújo*

Department of Dermatology and Venereology, Hospital de Braga, Braga, Portugal
[a]ORCID: 0000-0002-3247-2470

A 65-year-old man with a history of alcohol abuse presented with cicatricial alopecia and whitish sclerotic plaques in the upper chest, distributed mainly on the V area of the lower neck and lower sternum (Fig. 1). In addition, physical examination revealed a hyperpigmented area of hypertrichosis on the interparietal and left parietal region (Fig. 2).

Laboratory evaluation showed iron overload and elevated transaminases. Antinuclear antibodies and infectious serologies, including borrelia, were negative. A cutaneous biopsy of the scalp and neck was compatible with morphea, and thus, narrow band ultraviolet B phototherapy was initiated.

One month later, the patient reported blistering and crusting of the forearms. Urine analysis revealed increased uroporphyrins establishing the diagnosis of porphyria cutanea tarda (PCT). The patient was started on bimonthly phlebotomies, and photoprotection and alcohol withdrawal were recommended.

Sclerodermiform changes have been reported in 2% of PCT patients[1,2]. Clinically, lesions may resemble morphea, presenting with hyperpigmentation rather than a peripheral lilac ring[3,4]. Scalp lesions may present as scarring alopecia, also called alopecia porphyrinica[3]. Isolated sclerodermiform changes, without the typical clinical picture of PCT, pose a diagnostic challenge. Histopathology

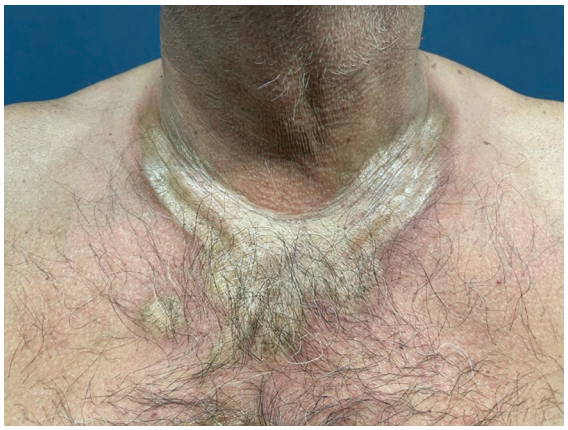

Figure 1. White-yellow atrophic plaques in the "V" area of the upper chest with a hyperpigmented border.

***Correspondence:**
Maria J. Guimarães
E-mail: mjcunhaguimaraes@gmail.com

Received: 20-04-2023
Accepted: 26-07-2023
DOI: 10.24875/PJDV.23000030

Available online: 20-12-2023
Port J Dermatol and Venereol. 2023;81(4):293-294
www.portuguesejournalofdermatology.com

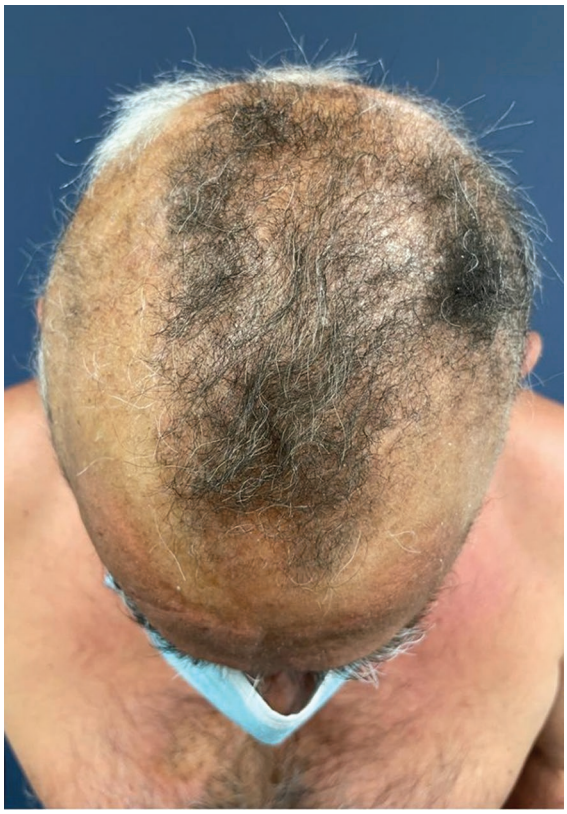

Figure 2. Alopecic patches on the scalp and hyperpigmented area of hypertrichosis on the interparietal and left parietal region.

cannot reliably distinguish morphea from sclerodermiform PCT[4]. Given the clinical and pathological resemblance, one must consider this alternative diagnosis, especially when facing therapy failure.

Funding

None.

Conflicts of interest

None.

Ethical disclosures

Protection of human and animal subjects. The authors declare that no experiments were performed on humans or animals for this study.

Confidentiality of data. The authors declare that they have followed the protocols of their work center on the publication of patient data.

Right to privacy and informed consent. The authors have obtained the written informed consent of the patients or subjects mentioned in the article. The corresponding author is in possession of this document.

Use of artificial intelligence for generating text. The authors declare that they have not used any type of generative artificial intelligence for the writing of this manuscript, nor for the creation of images, graphics, tables, or their corresponding captions.

References

1. Simon N, Korom I, Szekeres L, Morvay M, Kószó F. Sclerodermiform porphyria. Z Hautkr. 1986;61:1607-21.
2. Friedman SJ, Doyle JA. Sclerodermoid changes of porphyria cutanea tarda: possible relationship to urinary uroporphyrin levels. J Am Acad Dermatol. 1985;13:70-4.
3. Volksbeck SI, Nashan D, Bruckner-Tuderman L, Braun-Falco M. Localized sclerosis of the scalp (alopecia porphyrinica) as predominant presentation of porphyria cutanea tarda. J Eur Acad Dermatol Venereol. 2007;21:1125-7.
4. Stevens HP, Ostlere LS, Rustin MH, Black CM. Generalized morphoea secondary to porphyria cutanea tarda. Br J Dermatol. 1993;129:455-7.

Portuguese Journal of Dermatology and Venereology

Permanyer

Check for updates

Port J Dermatol and Venereol.

DERMATOLOGY IMAGES

Tractional alopecia

Alopecia tracional

Miguel Mansilla-Polo[1,2a], Begoña Escutia-Muñoz[1,2], and Rafael Botella-Estrada[1,2,3]*

[1]Department of Dermatology, Hospital Universitario y Politécnico La Fe; [2]Health Research Institute (IIS) La Fe; [3]Universitat de València. Valencia, Spain
[a]ORCID: 0000-0001-6730-6723

A 28-year-old woman, with no history of interest, consulted for hair loss for at least 10 years with no apparent associated trigger. On examination, a bilateral frontotemporal pillar loss was observed (Figs. 1A and 1B), coinciding with the area of tightness of her ponytail hairstyle. She related that ever since she could remember, she always combed her hair taut with a rubber band. On trichoscopy, fine hair was noted with no other trichoscopic findings, except for seborrheic dermatitis of the scalp. With the diagnosis of tractional

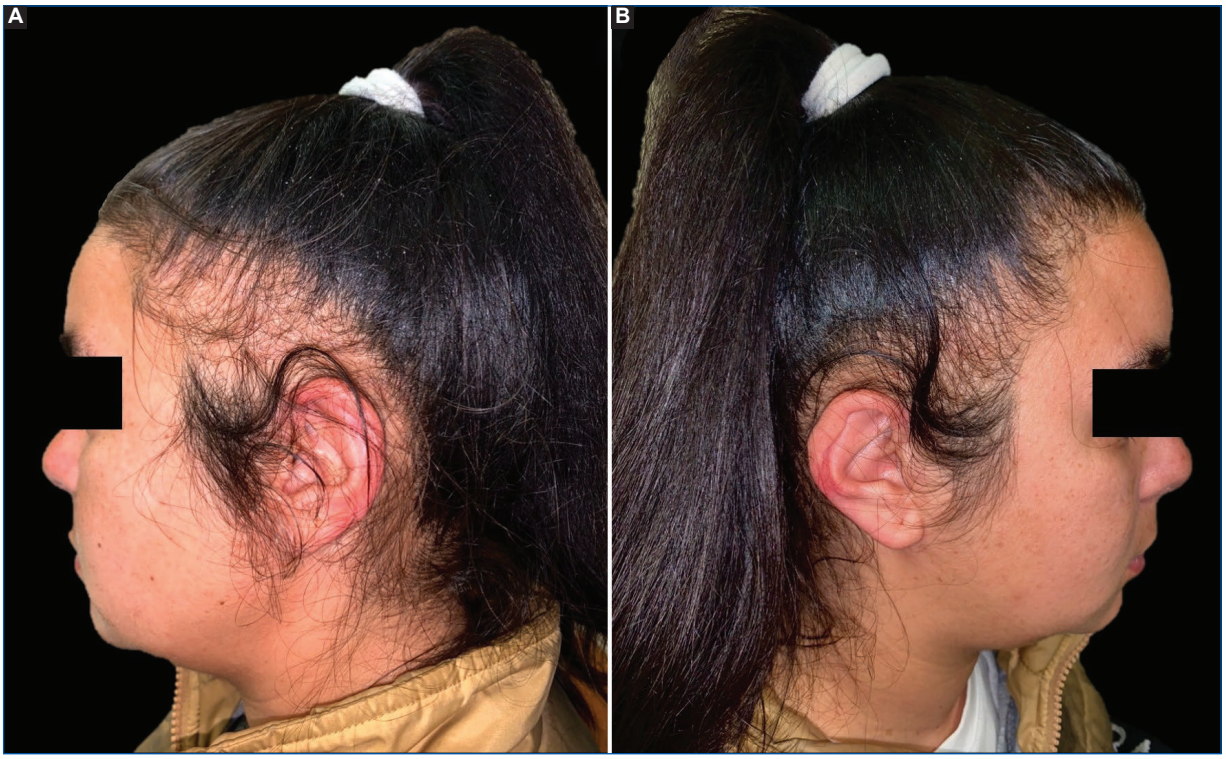

Figure 1. **A:** loss of the right and **B:** left frontotemporal pillar, in a linear fashion and limited to the region of greatest tension due to the ponytail. Seborrheic dermatitis of the scalp can also be observed.

***Correspondence:**
Miguel Mansilla-Polo
E-mail: miguel_yecla96@hotmail.com

Received: 14-05-2023
Accepted: 02-06-2023
DOI: 10.24875/PJDV.23000043

Available online: 28-08-2023
Port J Dermatol and Venereol. 2023;81(4):295-296
www.portuguesejournalofdermatology.com

alopecia, measures emphasizing the change of hairstyle and off-label use oral minoxidil 1mg/day werre initiated, with evident improvement after 3 months of treatment.

Tractional alopecia is a type of alopecia caused by continuous exposure to pulling forces on the scalp, typically pigtails, rubber bands or helmets, which initially cause reversible hair loss, but without treatment, lead to scarring alopecia[1,2]. Its early recognition by every doctor and the recommendation to avoid elements that pull the hair are important.

Funding

None.

Conflicts of interest

None.

Ethical disclosures

Protection of human and animal subjects. The authors declare that the procedures followed were in accordance with the regulations of the relevant clinical research ethics committee and with those of the Code of Ethics of the World Medical Association (Declaration of Helsinki).

Confidentiality of data. The authors declare that they have followed the protocols of their work center on the publication of patient data.

Right to privacy and informed consent. The authors have obtained the written informed consent of the patients or subjects mentioned in the article. The corresponding author is in possession of this document.

Use of artificial intelligence for generating text. The authors declare that they have not used any type of generative artificial intelligence for the writing of this manuscript, nor for the creation of images, graphics, tables, or their corresponding captions.

References

1. Larrondo J, McMichael AJ. Traction Alopecia. JAMA Dermatol 2023 May 3.doi: 10.1001/jamadermatol.2022.6298. Epub ahead of print. PMID: 37133879.
2. Awad A, Chim I, Sharma P, Bhoyrul B. Low-dose oral minoxidil improves hair density in traction alopecia. J Am Acad Dermatol. 2023 Feb 25:S0190-9622(23)00278-5. doi: 10.1016/j.jaad.2023.02.024. Epub ahead of print. PMID: 36842503.

Portuguese Journal of Dermatology and Venereology

Permanyer

Check for updates

Port J Dermatol and Venereol.

DERMATOLOGY IMAGES

Cyclosporine-induced hair repigmentation

Repigmentação capilar induzida pela ciclosporina

Ana L. Matos[a], Joana Calvão[b], and Inês Coutinho[c]*

Department of Dermatology, Coimbra University Hospital Center, Coimbra, Portugal
ORCID: [a]0000-0003-1441-0601; [b]0000-0002-1161-269X; [c]0000-0002-5371-7465

Hair graying is a sign of aging that results from complex melanogenesis regulation, determined by multiple intrinsic and extrinsic factors. Treatment options for canities are currently under investigation. Drug-induced hair repigmentation is infrequently reported in the literature. Available reports document hair repigmentation following treatment with psoralen or vitamin supplementation, but also with anti-inflammatory medications (such as thalidomide, adalimumab, acitretin, prednisone, or cyclosporin), stimulators of melanogenesis (latanoprost, erlotinib, imatinib, tamoxifen, and levodopa), clofazimine, or captopril[1].

A 76-year-old male was diagnosed with urticarial dermatitis, following complete clinical, analytic, and histological work-up. His chronic medication included bisoprolol, furosemide, *Serenoa repens,* and rosuvastatin. Treatment was initiated with a 4-week tapering course of oral prednisolone. Then, cyclosporine was introduced (3.5 mg/kg/day). Three months later, there was significant clinical response. At that same time, the patient reported hair repigmentation following several years of canities. There was no other identifiable cause, other than cyclosporine treatment, for this atypical complaint. Therapy was maintained for 9 months. Hair whitening resumed 2 months after its cessation and there was canities at 11-months follow-up.

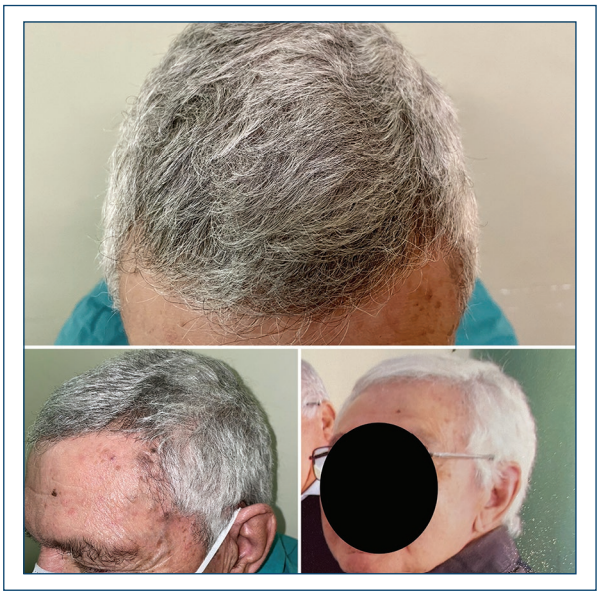

Figure 1. Complete hair repigmentation after several years of canities.

Case reports of hair repigmentation attributed to drugs known to inhibit pro-inflammatory cytokine activity are relatively scarce and treatment duration ranges from 2 to 24 months[1]. To the best of our knowledge, only two other cases of hair repigmentation induced by cyclosporine have been reported[2,3]. The mechanism supporting this association is relatively unknown. Pro-inflammatory cytokines seem to inhibit melanogenesis and aging melanocytes may induce an inflammatory environment

***Correspondence:**
Ana L. Matos
E-mail: ana.luisa.rodrigues.matos@gmail.com

Received: 22-05-2023
Accepted: 14-07-2023
DOI: 10.24875/PJDV.23000044

Available online: 30-08-2023
Port J Dermatol and Venereol. 2023;81(4):297-298
www.portuguesejournalofdermatology.com

around the hair follicle bulb. The inhibition of these cytokines may resume melanogenesis[1]. Even though only a limited number of patients treated with such drugs develop hair repigmentation, these reports show that hair graying might not be an irreversible process.

Funding

None.

Conflicts of interest

None.

Ethical disclosures

Protection of human and animal subjects. The authors declare that no experiments were performed on humans or animals for this study.

Confidentiality of data. The authors declare that they have followed the protocols of their work center on the publication of patient data.

Right to privacy and informed consent. The authors have obtained the written informed consent of the patients or subjects mentioned in the article. The corresponding author is in possession of this document.

Use of artificial intelligence for generating text. The authors declare that they have not used any type of generative artificial intelligence for the writing of this manuscript, nor for the creation of images, graphics, tables, or their corresponding captions.

References

1. Yale K, Juhasz M, Mesinkovska NA. Medication-induced repigmentation of gray hair: a systematic review. Skin Appendage Disord. 2020;6:1-10
2. Sadighha A, Zahed GM. Hair darkening after treatment with cyclosporin in a patient with psoriasis. J Eur Acad Dermatol Venereol. 2008;22:1239-41.
3. Rebora A, Delmonte S, Parodi A. Cyclosporin A-induced hair darkening. Int J Dermatol. 1999;38:229-30.

Portuguese Journal of Dermatology and Venereology

Permanyer

Check for updates

Port J Dermatol and Venereol.

LETTER TO THE EDITOR

Atypical presentation of anti-NXP-2 positive juvenile dermatomyositis

Manifestação atípica de dermatomiosite juvenile com anti-NXP-2 positivo

*Andreia Coimbra-Sousa, Renata Miossi, Fernando H. C. de Souza, and Samuel Katsuyuki-Shinjo[a]**

Division of Rheumatology, Faculdade de Medicina FMUSP, Universidade de São Paulo, São Paulo, Brazil
[a]ORCID: 0000-0002-3682-4517

Dear Editor,

The anti-NXP-2 is one of a myositis-specific autoantibody considered a marker of dermatomyositis (DM)[1,2]. In addition, there is a strong relationship between NXP-2 autoantibodies and calcinosis, particularly in juvenile DM[2]. In this context, we reported an atypical presentation and evaluation of a patient with anti-NXP-2 positive juvenile DM.

A female patient presented with whitish papules on her right forearm at 8 years of age. Seven years thereafter, the patient had proximal muscle weakness of the upper and lower limbs associated with transmission dysphagia, elevated CPK (maximum 350U/L), magnetic resonance imaging of the thighs with evidence of muscle edema, and a non-specific muscle biopsy. There was calcinosis over the previous lesion on the right forearm (Fig. 1A) as well as on other pressure points (such as armpits and posterior face of the knees). She denied any cutaneous changes, including heliotrope rash, Gottron's papules, and sign. A skin biopsy of the whitish papules revealed mild perivascular and perianexal dermatitis with foci of vacuolar alterations at the basal epidermal layer and dermal mucinosis. With the diagnostic hypothesis of an inflammatory myopathy, she was treated with high-dose oral glucocorticoid 1 mg/kg/day, methotrexate (20 mg/week), colchicine (1.0 mg/day), and a calcium channel blocker with a sustained clinical and laboratorial response, except for a minor muscle outbreak at the beginning of the disease. Glucocorticoid was discontinued after three years and

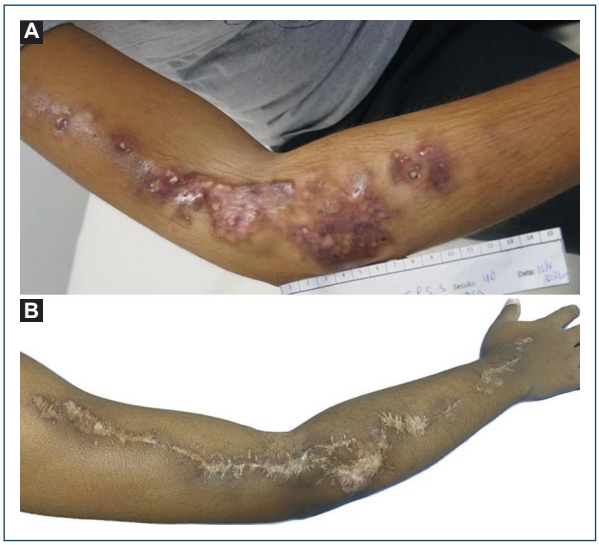

Figure 1. A: cutaneous calcinosis in the right upper limb, where previously was a hypopigmented lesion.
B: appearance of the right upper limb after one year of surgical removal of the calcinosis.

***Correspondence:**
Samuel Katsuyuki-Shinjo
E-mail: samuel.shinjo@usp.br

Received: 02-10-2023
Accepted: 21-10-2023
DOI: 10.24875/PJDV.23000080

Available online: 20-12-2023
Port J Dermatol and Venereol. 2023;81(4):299-300
www.portuguesejournalofdermatology.com

methotrexate dose was reduced from 20 to 15 mg/week. There was no further calcinosis and the patient decided to undergo surgical removal of the old ones in 2022 (Fig. 1B). In March 2023 at the age of 20 in our tertiary service, she was clinically and laboratory-stable and specific autoantibodies for myositis were strong positive only for anti-NXP-2 autoantibody (EUROLINE autoimmune myositis 16 Ag, Euroimmun, Lübeck, Germany).

In conclusion, myositis-specific antibodies can contribute to the diagnosis of DM, especially in cases of atypical presentation, as in the reported case.

Funding

None.

Conflicts of interest

None.

Ethical disclosures

Protection of human and animal subjects. The authors declare that the procedures followed were in accordance with the regulations of the relevant clinical research ethics committee and with those of the Code of Ethics of the World Medical Association (Declaration of Helsinki).

Confidentiality of data. The authors declare that they have followed the protocols of their work center on the publication of patient data.

Right to privacy and informed consent. The authors have obtained the written informed consent of the patients or subjects mentioned in the article. The corresponding author is in possession of this document.

Use of artificial intelligence for generating text. The authors declare that they have not used any type of generative artificial intelligence for the writing of this manuscript, nor for the creation of images, graphics, tables, or their corresponding captions.

References

1. Toplak N, Chavan PP, Rosina S, Dallos T, Rotem Semo O, Aguiar CL, et al. Is anti-NXP2 autoantibody a risk factor for calcinosis and poor outcome in juvenile dermatomyositis patients? Case series. Front Pediatr. 2022;9:810785.
2. Tansley SL, Betteridge ZE, Shaddick G, Gunawardena H, Arnold K, Wedderburn LR, et al. Calcinosis in juvenile dermatomyositis is influenced by both anti-NXP2 autoantibody status and age at disease onset. Rheumatology (Oxford). 2014;53:2204-8.